




THE TRICHY OBSTETRICS AND GYNECOLOGICAL SOCIETY



26TH ANNUAL CME
5th & 6th August, 2023




A Step Ahead in Unravelling Mysteries

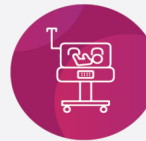

Department of Obstetrics and Gynaecology & Neonatal Intensive Care Unit (Saving the Unsavable)



Obstetrics and Gynaecology Services:

- 24X7 Maternity Services
- 24X7 High Risk Obstetrics
- Painless Normal Delivery
- Advanced Laparoscopic Gynaecologic Surgeries
- Urogynaecology Services
- Gynaecologic oncology
- Mammogram
- Exclusive Well Woman Counselling Clinic (PCOD / ADOLESCENT / INFERTILITY / MENOPAUSE)
- Exclusive mother and child care / IVF / Fetal medicine



Neonatal Intensive Care Unit Services: For Intact Survival

- NNF (National Neonatology Form Level IIIA Accredited Unit)
- 24x7 Newborn Resuscitation Team
- 24x7 Sick Newborn Transport Team
- Exchange Transfusion & Peritoneal Dialysis
- Extremely Lowbirth Weight Newborn Care
- Neonatal Transport Incubator and Ventilator
- Advanced Ventilation & HFNC
- 24x7 In - house Paediatrician & Neonatologist
- State of Art NNF Fellowship Program for Paediatrician (Post MD & DCH) & Nurses

WORLD CLASS PANEL OF DOCTORS

STATE OF ART EQUIPMENT

BEST IN CLASS AMENITIES

#6, Royal Road, Cantonment, Trichy-620001. Ph: **0431-4077777**

E: info@kauveryhospital.com | W: www.kauveryhospital.com



President

Dr. Malathi G Prasad

Vice President

Dr. Thamilselvi Mathivanan

Dr. Victoria Johnston

Secretary

Dr. Lakshmi Prabha

Joint Secretary

Dr. Uma Velmurugan

Treasurer

Dr. Vijayaprabha Chezhiyan

Executive Committee Members

Dr. DeepaMukhundhan

Dr. Abiraami Karpagam

Dr. Gayathri Mathrubootham

Dr. ShreLakshme

Dr. J.Prabha

Dr. Shilpa Gandhi

Dr. Akila Vaidyanathan

Dr. Priyanka Velchamy

with best compliments



SUNDARAM — HOSPITAL —

17, E.V.R. Road, Puthur, Trichy - 620017.

Phone: 0431 - 4024444

DEPARTMENTS

- Diabetes & Critical Care
- Interventional Cardiology
- Cardio Thoracic Surgery
- Nephrology & Renal Transplant
- Gastroenterology
- Neurology & Neuro Surgery
- Plastic Surgery & Diabetic Foot Clinic
- Orthopaedics & Trauma Care
- Arthroscopy & Knee Replacement
- Urology
- Obstetrics & Gynecology
- Vascular Surgery
- CT Scan & Interventional Radiology





WORLD BREAST FEEDING WEEK




CERVICAL CANCER SCREENING



BADLAAV CLINIC




PONGAL VIZHA



Friendship day





INTERNATIONAL YOGA DAY

WORLD DOWN'S SYNDROME DAY





PRESIDENT'S MESSAGE



Dear Friends and Colleagues,

We are stepping into the 26th annual CME to be held on 5th and 6th August 2023.

The CME is preceded by 2 workshops on Fetal Medicine and Hysteroscopy.

The CME will be on topics updating us in the Field of Obstetrics and Gynaecology.

The journal has lots of interesting topics and will be of immense help for the practising Obstetricians and Gynaecologists. The journal will be released on 6th August on the day of the CME.

I must thank the editorial team for their extreme efforts in releasing the journal.

Wishing us all an academic feast.

Dr Malathi G .Prasad, MD,FRCOG.



SECRETARY'S MESSAGE



Dear Friends and Colleagues,

Aadi Peruku greetings to all.

Aadi is a new beginning for most of the festivals. It is indeed a great pleasure to release our TRIOGS Journal in our 26th Annual CME.

Trichy O&G Society has been regarded as one of the best societies in FOGSI for our unity, work and contribution. We are proud to have many Vice Presidents of FOGSIas TRIOGSians.

“Unity is Strength

When there is Teamwork and collaboration wonderful things can be achieved.”

“We are not a team just because we work together, we are a team only because we respect , trust and help each other.”

I congratulate the Journal Team.

Dr. Vijaya Prabha Chezian

Dr. Thamizhselvi Naveen

Dr. Sithara.D

Dr. Rajailavarasi

For their great efforts in bringing this Journal

**“If you want to go fast go alone. If you want to go far go together”
Long Live TRIOGS.**

Dr. Lakshmi Prabha MBBS., DGO., DNB. (OG).,



FROM THE EDITOR'S DESK



DR. VIJAYA PRABHA CHEZHIAN
MBBS DGO FICOG



DR. D. SITHARA,
MBBS, MS(OG), FRM



DR. THAMIZHSELVI NAVEEN
MD(OG), DNB (OG), FRM



DR RAJA ILAVARASI
MBBS MS DNB OG, FRM

As TRIOGSeans we take great pride and privilege in presenting this Silver Journal, to you all.

In the words of Albert Einstein

"The significant problems we face cannot be solved at the same level of thinking we were at when we created them"

To learn, unlearn and relearn we have all joined hands to share our experiences and case based studies from different Government and Private Institutions,

Information from these studies will help us to complete our own data, if done meticulously.

We would like to immensely thank our president Dr. Malathi Prasad and our secretary Dr. Lakshmi Prabha for giving us the freedom and fresh air, in the making of this journal and special thanks to all doctors, who have helped by sharing their experiences as case based studies with us.

INDEX

Sl.No	TOPICS	Author	Page No
1	ART IN PERI-MENOPAUSE	DR. T. RAMANI DEVI, MD., DGO., FICS., FICOG., DR. A. RIFANA PARVEEN, DGO., DNB., FRM.,	1
2	CALCIUM! CALCIUM! EVERYWHERE. WHICH TO CHOOSE ? BEYOND BONE – BENEFITS OF CALCIUM IN PREGNANCY	DR. SRIPRIYA PRAGASAM, MD, FICS, FICOG	5
3	VENTRAL CONJOINED TWINS OF THORACO- OMPHALOPHAGUS TYPE - A CASE REPORT	DR MALATHI G PRASAD, DR REVATHY M C ,	10
4	ACUTE PANCREATITIS IN PREGNANCY	DR. VICTORIA JOHNSTON M.D,F.I.C.S, F.I.C.O.G	13
5	MATERNAL CONGENITAL COMPLETE HEART BLOCK IN PREGNANCY A RARE CASE REPORT.	DR. LAKSHMI PRABHA MBBS., DGO., DNB. (OG).,	18
6	RARE CASES OF UTERINE TORSION.	DR PUNITHA RAJESH, MD(OG)., FICOG., DGES(GERMANY)	22
7	A CASE OF SPONTANEOUS SPLENIC RUPTURE IN TERM PREGNANCY CAUSING INTRAUTERINE FOETAL DEATH: A RARE ENTITY	DR. N.THANTHONI, D.N.B (OG)	23
8	LAW IN MEDICAL PRACTICE – A FEW PRACTICAL TIPS	DR. GAYATHRI. N. M.D., DNB, PGDMLE.	25
9	LETHAL SKELETAL DYSPLASIA: RARE BUT CONCERNING.	DR.LOHA PUSHPANJALI.L. MD OG	27
10	FERTILITY PRESERVATION	DR.PRIYADHARSHINI MOHANASUNDARAM MBBS, MD, MRCOG (UK), MICOG,	29
11	SKELETAL DYSPLASIA - A GENETIC CASE REPORT	DR MALATHI G PRASAD, DR REVATHY M C ,	35
12	ARTIFICIAL INTELLIGENCE (AI) IN INFERTILITY	DR. THAMIZHSELVI NAVEEN, MD(OG), DNB(OG),FRM	37
13	PREGNANCY IN PARTIAL EMPTY SELLA SYNDROME “ A CASE OF PRIMARY AMENORRHEA”	DR.KASTHURI.C , DGO., DNB. (OBG),	43
14	CLINICAL UPDATES IN THE DETECTION OF PRE- ECLAMPSIA – AN OVER VIEW BY AN OBSTETRICIAN AND FETAL MEDICINE CONSULTANT	DR.RAJA ILAVARASI, MBBS, MS, DNB OG, FRM DR. KARTHIK SENTHILVEL MBBS, MDRD, PDF	48
15	ROLE OF VITAMIN-D AND INFERTILITY- A COMPREHENSIVE REVIEW	DR.HARSHINI JAYAKUMAR, MBBS DGO DNB	52
16	A CASE OF HYPEREMESIS GRAVIDARUM INDUCED HYPOKALEMIC PARALYSIS	DR. J JANICE ALPHONSA, SECOND YEAR OG PG GUIDE: DR. PUNITHAVATHI M.S OG	56
17	A CASE OF FORGOTTEN LIPPES LOOP OR IUCD IN POST MENOPAUSAL WOMEN LEADING TO POST MENOPAUSAL BLEEDING AND PYOMETRA	DR.KEERTHANA S, SECOND YEAR POST GRADUATE GUIDE :DR.PUNITHAVATHI M.S OG (ASSOCIATE PROFESSOR)	58
18	A RARE CASE OF ADENOSARCOMA – HISTOLOGICAL SURPRISE	DR. B.C. SAMYUKTHA, FIRST YEAR OG PG GUIDE – DR. PUNITHAVATHI M.S OG	60
19	DIAGNOSTIC DILEMMA AT TERM-ADNEXAL MASS DURING C SECTION	DR.PRITIKA, FIRST YEAR OG PG, GUIDE: DR.J.PUNITHAVATHI MS OG,	63
20	A CASE OF UNICORNUATE UTERUS WITH UNILATERAL ABSENT OVARIES	DR.S E SWETHA, FIRST YEAR OG PG GUIDE: DR.J.PUNITHAVATHI MS,OG.	67
21	ARNOLD CHIARI MALFORMATION – A CASE REPORT	PRESENTOR : DR. K. SHOBAPRIYA 1YR MS OG PG GUIDE : DR PUNITHAVATHY MS OG	69
22	POEM	DR.K.VIJAYA PRABHA CHEZHIAN, MBBS,DGO,FICOG	72



**DR. T. RAMANI DEVI, MD., DGO., FICS., FICOG.,
DIRECTOR RAMAKRISHNA MEDICAL CENTRE LLP
DIRECTOR JANANI FERTILITY CENTRE, TRICHY**

**DR. A. RIFANA PARVEEN, DGO., DNB., FRM.,
RAMAKRISHNA MEDICAL CENTRE LLP, TRICHY**

ART IN PERI-MENOPAUSE



Women over 40 years of age seeking infertility treatment has been steadily increasing in the past decade due to women acquiring higher education, career orientation, financial stability and remarriages.¹ Women seeking fertility treatment at a later age pose challenges to the consultant. There is declining fertility by the age of 30 years, and after 35 years it declines rapidly and practically no pregnancy beyond 45 years. Even if the patient conceives, there is reduced successful conception rate and increase in the miscarriage rate. There is decrease in oocyte retrieval rate with increasing age leading to decreased number of oocytes, concomitant increase in the rate of oocyte aneuploidy thereby leading to reduced reproductive potential. Biological age, which can be defined as a woman's specific reproductive competence or ovarian reserve, can be entirely different from her chronological age.² It is hypothesized that the decline in oocyte quality as women ages is not simply due to the time-related effect of increased exposure to accidental damage, but rather that the defective oocytes were defective from the very start, during foetal ovarian development. These defective oocytes are recruited relatively late in life, carrying an increased risk of aneuploidy and miscarriage.² Current options available for fertility in peri-menopausal women are ovulation induction (OI) with intra uterine insemination (IUI), Assisted Reproductive Technology (ART), embryo/oocyte donation, embryo or oocyte cryo-preservation and rarely stem cell therapy.

OI with IUI

Among women greater than 40 years, the pregnancy rate is 17.9% per insemination and live birth rate per insemination is 8.5%.³ For women aged 43 years and beyond, the live birth rate per insemination is 4.2%. GnRH-a and FSH stimulation for insemination was associated with a live birth rate per insemination of 12.5%.⁴ It is reasonable to include superovulation and

IUI as a possible fertility treatment for couples with a female age of 43 years in whom there is no evidence of tubal disease or severe male factor infertility.³

ART

Reproductive Medicine and Medical Cytogenetics Department, Regional University Hospital and School of Medicine, France has studied 500 IVF/ICSI cycles > 40 years (January 2007 to December 2011) and found biochemical pregnancy was 17.6%, ongoing pregnancy was 8.9%, and live birth rate was 7.4% among women greater than 40 years. Published studies report a clinical pregnancy rate of 10–15% in women undergoing IVF or ICSI. Long protocol produces more oocytes (5.3 versus 3.3) but there was no significant difference in the number of transferred embryos and in the delivery rate. Significantly there is less duration of stimulation and FSH dose with GnRH antagonist use compared to GnRH agonist protocol. Long agonist and antagonist regimens better than short GnRH agonist regimen which is less effective as it can result in elevated progesterone levels in early follicular phase.⁵ A meta-analysis showed that the supplementation of various ovarian stimulation protocols with recombinant LH seems to improve the implantation and clinical pregnancy rates in women over 35 years of age. Implantation and clinical pregnancy were higher in the recombinant LH-supplemented group. Mild stimulation protocol associated with low dose of gonadotropins with antagonist is also an interesting alternative for patients with poor ovarian reserve. Compared to classical protocols this alternate protocol may produce more good quality embryos, better implantation and pregnancy rates when the same number of embryos are transferred. Trans-dermal testosterone patches, GH/GHRF play a role as adjuvants. DHEA, LDA and L-Arginine have doubtful role as adjuvants. Addition of GH has a beneficial effect on the probability of LBR but



no beneficial effect on adding GHRF. Addition of pyridostigmine does not appear to improve the ongoing PR or LBR. Adding low dose aspirin has a beneficial effect but not currently supported. DHEA pretreatment cannot increase CPR, LBR or COCs retrieved. Transdermal testosterone pretreatment is associated with decrease duration and total dose of gonadotrophins, increase number of COC retrieved, additional 15% increase in CPR, 11% increase in LBR. Addition of L-arginine increases the number of oocytes retrieved but no beneficial effect on pregnancy rate. In women with diminished ovarian reserve, it seems reasonable to proceed directly to IVF given that the chances of conceiving with clomiphene or with gonadotrophins are low.⁵ If ovarian reserve is optimum in women over 40 years of age, a trial of gonadotrophin ovarian stimulation and IUI may be indicated.

Embryo/oocyte donation

Among infertile women over 40 years of age can be treated with IVF/ICSI, using donated oocytes from young patients as a good efficient alternative to improve their pregnancy and delivery rates. In practice, embryo donation is more commonly used in cases of combined male and female infertility, especially if specific genomes and/or epigenome decays are diagnosed and not corrected after multiple treatments. A clinical pregnancy rate of 53.4% per cycle with a delivery rate of 42.6% has been reported in a Spanish experience. Cumulative pregnancy rate after 4 cycles of embryo transfer is nearly 94%, showing no effect of the recipient patient's age on the efficiency of oocyte donation programme.⁷ The risks associated with ovarian stimulation among patients over 40's can be avoided through oocyte or embryo donation. Obstetrical complications such as gestational diabetes, pre-eclampsia and thrombosis should be considered in older patients even with oocyte or embryo donation and hence perfect maternal screening is mandatory prior to ART. In practice embryo donation is the most commonly used in cases of combined male and female infertility, especially if specific genomes and/or epigenome decays are diagnosed and not corrected after multiple treatments.

Oocyte/embryo cryopreservation

Prof. Christopher Chen in Australia, in 1986 pioneered the world's first birth through oocyte freezing and thawing. Oocytes are difficult cells to cryopreserve,

reasons being larger size, very sensitive to low temperature, extremely fragile, high-water content, low surface to volume ratio, presence of the spindle and other cell organelles, nonoptimal plasma membrane permeability to CPA and water. In 2012, the "experimental" label for OC was removed by ASRM and ESHRE and OC has increased to 18.6% in 1 year from 6123 cycles in 2014 to 7518 cycles in 2015. Retrospective multi-centre study spanning an 8-year time period evaluating 1468 women undergoing elective oocyte cryopreservation showed that oocyte survival rate in women ≤ 35 years and ≥ 36 years were 94.6% vs. 82.4%, respectively. Live birth rates for women undergoing OC ≤ 35 years and ≥ 36 years were significantly different, with 50% and 22.9% respectively. Age was associated with success even in the cohort of women undergoing OC ≤ 35 years, with live birth rates of 100% ≤ 29 years, 45% at 30–34 years, 28.5% at 35–39 years, and 3.7% at ≥ 40 years. According to Stoop et al nearly 22 vitrified metaphase II oocytes are needed to achieve pregnancy in women aged between 23 and 37 years. Knowing that the average number of collected oocytes is 8 per stimulation cycle in this age group, this implies that 2–3 ovarian stimulations and oocyte pick up cycles are needed to achieve a live birth. A minimum of 55 vitrified metaphase II oocytes is needed to achieve a pregnancy in women aged 38–43 years. For all ages Cobo et al., 2014⁸ recommend that at least 12 metaphase II vitrified oocytes are needed to achieve clinical pregnancy in an oocyte cryopreservation programme. Risks of OC must be discussed with patients undergoing the procedure. Major complications for patients are low (<1%) and include risks during oocyte retrieval including infection, damage to organs, blood loss, ovarian torsion, and risks related to anaesthesia. Most common risk is OHSS (<5%). A study evaluating 4052 oocyte donors revealed a risk of moderate to severe OHSS <1% which was eliminated with the use of a GnRH antagonist protocol and GnRH agonist trigger.⁹ Data are limited and more long-term data are needed, to assess that there is no risk to offspring related to OC. If the women or the couple plan for late family, it is better to go for cryopreservation at an earlier age, as the survival rate and LBR comes down as maternal age goes up. A study of 1027 children born from 804 pregnancies using vitrified oocytes compared to 1224 children from 996 pregnancies with IVF using fresh oocytes revealed no significant differences in obstetrical outcomes, gestational age at delivery, birthweight, birth defects, APGAR scores, or perinatal

mortality between cryopreserved and fresh oocytes. Cryopreservation of embryo is the most relevant and well-established option for fertility preservation and was the only method endorsed by the ASRM until 2012. The effectiveness and safety of this option have been proved so that this technique is routinely used in ART centres for infertile women to store supernumerary embryos, prevent ovarian hyperstimulation syndrome (OHSS) and in cases of impaired endometrial development and impractical embryo transfer. Although the success rate of oocyte vitrification is increasing, embryo cryopreservation, based on obtained satisfactory rate, is still the best option that can be offered to post-pubertal women who desire fertility preservation, especially for those who are mature and have enough time prior to onset of aggressive treatments and have a partner or sperm donor as well.¹⁰ Embryo cryopreservation has, however, generated ethical, moral and legal issues. Some countries have enacted specific laws that restrict (e.g. Germany, Switzerland, Austria) or even forbid (Italy with Law 40 in 2004) embryo cryopreservation. Oocyte CP offers more advantages compared to Embryo Freezing. Fertility preservation in women at risk of losing fertility due to oncological treatment, POF or chronic disease. Oocyte CP can help alleviate religious and/or other ethical, legal, and moral concerns of embryo storage. Oocyte CP helps to overcome problems such as when the husband is unable to produce a viable sperm sample or when spermatozoa cannot be found in the testis at a given moment in case of non-obstructive azoospermia. Oocyte CP makes "egg banks and/or egg donations" possible by eliminating donor-recipient synchronization problems. Oocyte CP allows women to postpone childbirth until a later time or age (e.g., after establishing a career, etc.)

Stem cells: Today's Science... Tomorrow's Future

Ability to generate new oocytes, the treatment of Asherman's syndrome and recurrent implantation failures due to poor endometrial receptivity have all been addressed with the treatment of stem cells in various research centres across the globe. However, these are under various stages of research at approved highly advanced centres with strict enrolment and monitoring criteria. Young women with POI may be able to use their own bone marrow stem cells to rejuvenate their ovaries and avoid the effects of

premature menopause as new research suggests in a paper presented at the 100th Meeting of the Endocrine Society in March 2018 at Chicago.

Techniques which are still experimental and hold promise for the future

Ovarian tissue cryopreservation and re-implantation, ovarian rejuvenation with stem cells taken from autologous ovarian cortex, oocyte augmentation procedures like mitochondrial transfer, regeneration of endometrium with the help of bone marrow stem cells or PRP and finally uterine transplant are various successful procedures now.

Key points

- •IUI over women of 40 is associated with a low rate of ongoing pregnancy and it should not therefore be offered always as the first line of treatment.
- •When the predictive factors are positive, IVF/ICSI seem to be good alternatives until 43 years of age.
- •Customized ovarian stimulation and flexible laboratory methods such as in vitro maturation (IVM), PGD, embryo vitrification and transfer after thawing in subsequent natural or artificial cycles can improve the outcome of ART in patients over 40.
- •Oocyte and embryo donation remain good options for patient over 40 with a bad prognosis and can lead to successful ongoing pregnancies.
- •Ovarian tissue cryopreservation, oocyte vitrification at the germinal vesicle (GV) stage or metaphase II stage present a breakthrough for fertility preservation.
- •All couples should undergo thorough fertility and metabolic evaluation before commencing ART.
- •Low AMH levels must be considered as a reason to discuss ART sooner rather than later.
- •In women over 40 with very low AMH, consideration for donor eggs must be given.
- •Patients with advanced maternal age have worse ART outcomes, and are less likely to progress through each stage of ART.
- •Pregnancy in the older woman is more likely to be complicated by miscarriage, gestational diabetes, preeclampsia, preterm delivery, caesarean section



and fetal low birth weight.

References

1. Kmietowicz, Zosia. "More women over 40 seek fertility treatment." (2007): 1187-1187.
2. Alviggi C, Humaidan P, Howles CM, Tredway D, Hillier SG. Biological versus chronological ovarian age: implications for assisted reproductive technology. *Reproductive Biology and Endocrinology*. 2009 Dec;7:1-3.
3. Haebe J, Martin J, Tekepety F, Tummon I, Shepherd K. Success of intrauterine insemination in women aged 40–42 years. *Fertility and sterility*. 2002 Jul 1;78(1):29-33.
4. Alyasin A, Mehdinejadani S, Ghasemi M. GnRH agonist trigger versus hCG trigger in GnRH antagonist in IVF/ICSI cycles: A review article. *International Journal of Reproductive BioMedicine*. 2016 Sep;14(9):557.
5. Revelli A, Chiadò A, Dalmaso P, Stabile V, Evangelista F, Basso G, Benedetto C. "Mild" vs."long" protocol for controlled ovarian hyperstimulation in patients with expected poor ovarian responsiveness undergoing in vitro fertilization (IVF): a large prospective randomized trial. *Journal of Assisted Reproduction and Genetics*. 2014 Jul;31:809-15.
6. Armstrong S, Akande V. What is the best treatment option for infertile women aged 40 and over?. *Journal of assisted reproduction and genetics*. 2013 May;30:667-71.
7. Ubaldi F, Anniballo R, Romano S, Baroni E, Albricci L, Colamaria S, Capalbo A, Sapienza F, Vajta G, Rienzi L. Cumulative ongoing pregnancy rate achieved with oocyte vitrification and cleavage stage transfer without embryo selection in a standard infertility program. *Human reproduction*. 2010 May 1;25(5):1199-205.
8. Cobo A, Serra V, Garrido N, Olmo I, Pellicer A, Remohí J. Obstetric and perinatal outcome of babies born from vitrified oocytes. *Fertility and sterility*. 2014 Oct 1;102(4):1006-15.
9. Bodri D, Guillén JJ, Polo A, Trullenque M, Esteve C, Coll O. Complications related to ovarian stimulation and oocyte retrieval in 4052 oocyte donor cycles. *Reproductive biomedicine online*. 2008 Jan 1;17(2):237-43
10. Selvaraj P, Selvaraj K, Srinivasan K. Successful birth of the first frozen oocyte baby in India. *Journal of Human Reproductive Sciences*. 2009 Jan;2(1):41.



DR. SRIPRIYA PRAGASAM, MD, FICS, FICOG
SRI VENKATESHWARA HOSPITAL, TRICHY

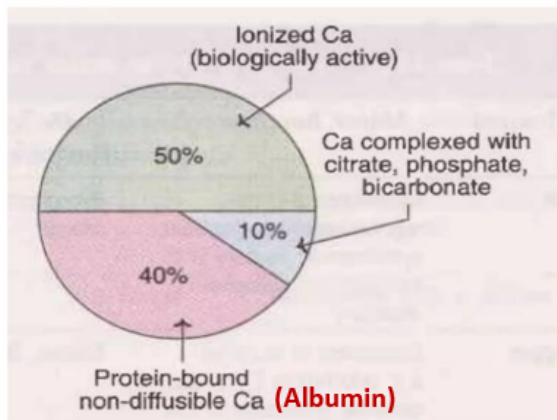
CALCIUM! CALCIUM! EVERYWHERE. WHICH TO CHOOSE ?
BEYOND BONE – BENEFITS OF CALCIUM IN PREGNANCY

Calcium is the most abundant mineral in the body. The total body calcium is between 1 – 1.5 kg. 99% is present in bones & teeth & the remaining 1% is present in body fluids & tissues.

Calcium, along with phosphate is required for the formation & physical strength of skeletal tissue. Bones which are in a dynamic state serve as reservoir of calcium. Calcium is essential for mechanisms like muscle contraction, blood coagulation, nerve transmission, membrane integrity & permeability, activation of enzymes, release of hormones & for its action on the heart.

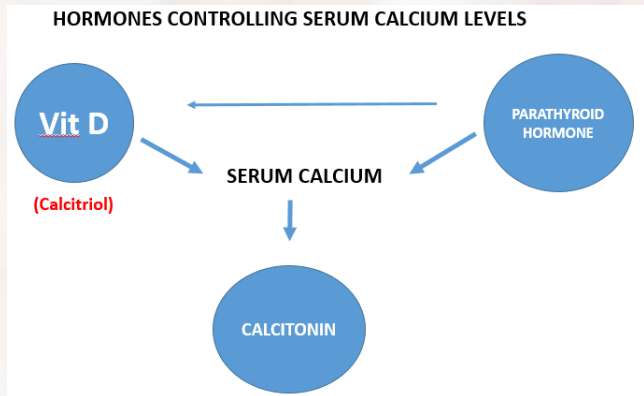
Different forms of circulating Calcium

Different forms of circulating calcium



Calcium homeostasis is a complex process involving calcium & three hormones.

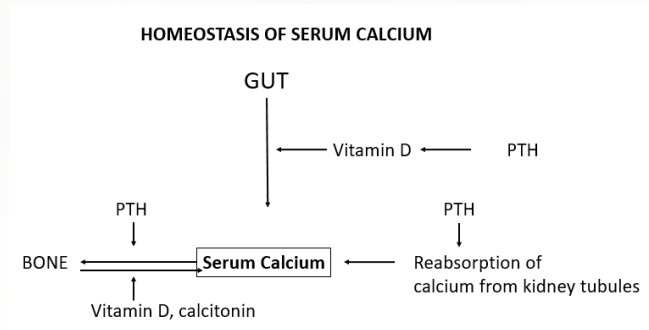
Vit. D (active form is also called calcitriol) is the only vitamin that can be synthesized in the body with the help of sunlight. It involves 2 hydroxylation (First (OH) occurs at the liver & the second (OH) occurs at the kidney) to produce the active form of vit.D which is 1,25 – dihydroxy vit. D3. Active Vit .D3 is important for calcium homeostasis.



Parathyroid hormone (PTH) is produced by parathyroid glands & its secretion is controlled by the negative feedback mechanism of serum calcium levels. The hormone acts at three independent sites - bone, kidney and intestine. PTH acts at all 3 sites to increase serum calcium level. From the bone, there is increased resorption, at the kidneys, there is increased tubular reabsorption of calcium & at the intestines, there is increased intestinal absorption. Thus both Vit D & PTH increase serum calcium level.

Calcitonin is on the opposite side. Overall it decreases serum calcium levels.

Calcitonin is secreted by para follicular cells of thyroid gland. Calcitonin increases the activity of osteoblast & promotes calcification, decreases bone resorption & increases excretion of calcium in urine.



Changes in pregnancy

In pregnancy, many physiological changes occur, to preserve maternal calcium homeostasis, while at the same time providing for fetal growth & development.

The normal physiological changes in pregnancy which have direct implications on calcium metabolism are falling albumin levels, expansion of extracellular fluid volume, increase in renal function & placental calcium transfer. [1]

Calcium homeostatic response during pregnancy includes increased intestinal calcium absorption, increase in urinary excretion of calcium & increased bone turnover.

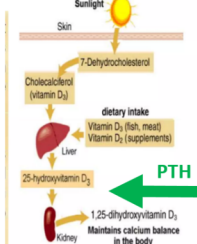
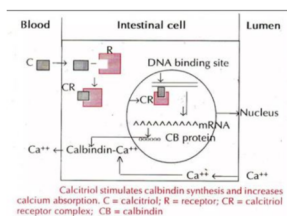
Maternal serum 1,25 (OH)₂ D levels increased two fold during pregnancy, allowing the intestinal absorption of calcium also to double. Serum 25-OH vit D (inactive form) levels do not change during pregnancy, but an increase in 1- alpha hydroxylase & additional synthesis in the placenta, allows for an increase in the conversion of 25 OH vit D to active form 1,25 (OH)₂ D

The mechanism of calcium absorption involves binding of calcium to a specific protein (Calmodulin – Calcium binding protein) whose synthesis is stimulated by active form of vit. D.

FACTORS STIMULATING INTESTINAL ABSORPTION OF CALCIUM

↑ Vit D
Formation of D3 receptor complex
↑ Calcium binding protein (Calmodulin)

PTH
Increase activity of 1 - ∞ hydroxylase enzyme



Although PTH levels do not increase above normal during pregnancy, levels of parathyroid hormone receptor protein (PTHrP) increases in maternal circulation. PTHrP protects the maternal skeleton from bone resorption by increasing both calcium absorption in the small intestine & tubular reabsorptions in the kidney.

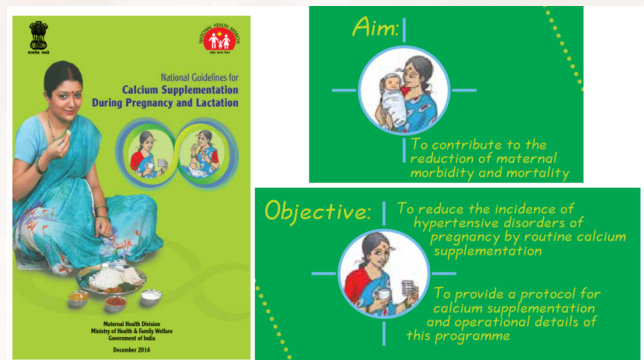
The increased intestinal absorption of calcium is directly related to maternal calcium intake. Ritchie et al reported that women with a daily average intake of 1171mg absorbed 57 % of dietary calcium during the second

trimester & 72% during the third trimester.

These changes maintain the serum ionic calcium level (Biologically active) within its characteristically narrow physiological range. However, even with these high rates of absorption, maternal & fetal needs may not be met in women with chronically low calcium consumption (<500mg/day)

The skeleton of a new born baby contains approximately 20 – 30gm of calcium. The bulk of fetal skeletal growth takes places from mid pregnancy onwards, with maximal calcium accretion occurring during the third trimester.

So, Calcium supplementation during pregnancy & lactation becomes an absolute necessity for our Indian women. National Guidelines has been formulated by the Ministry of Health & Family Welfare, Govt. of India as a National program.



According to the guidelines

- All pregnant and lactating women to be counselled about intake of calcium rich foods



- All pregnant and lactating women to be counselled about intake of calcium rich foods.

Annexure 4: Good Dietary Sources of Calcium

Food example	Amount	Calcium in milligrams
Milk	1 Cup	580
Butter Milk	1 Cup	232
Yogurt	1 Cup	452
Cheese	1 cubic inch	129
Ice cream	1 Cup	272
Sweet Potatoes	1 Cup	50-100
Green Beans	1 Cup	50-100

Even if you eat a healthy, balanced diet, you may find it difficult to get enough calcium if you:


- Follow a vegan diet
- Have lactose intolerance and limit dairy products
- Consume large amounts of protein or sodium, which can cause your body to excrete more calcium

- Are receiving long-term treatment with corticosteroids
- Have certain bowel or digestive diseases that decrease your ability to absorb calcium, such as inflammatory bowel disease or celiac disease

So, there is a need for calcium supplementation in all pregnant & lactating women in India.

Protocol for calcium supplementation

- Oral swallowable calcium tablets to be taken twice a day (total 1 gm calcium/day) starting from 14 weeks of pregnancy up to six months post-partum.
- One calcium tablet should be taken with the morning/afternoon meal and the second tablet with the evening/night meal. It is not advisable to take both calcium tablets together as > 800 mg calcium interferes with iron absorption. Calcium



Target population

All pregnant women in the community

tablets should not be taken empty stomach since it causes gastritis.

- Calcium and Iron Folic Acid (IFA) tablets should not be taken together since calcium inhibits iron absorption. IFA tablets should be taken preferably two hours after a meal.
- Each calcium tablet should contain 500 mg elemental calcium and 250 IU vitamin D3. The preferred formulation for calcium is calcium carbonate. The rationale for inclusion of Vitamin D is to enhance the absorption of calcium.

Side effects & contraindications

- None, within the recommended limit (1 gm/d).
- A small proportion of women may experience mild gastritis, so calcium tablets should be taken with meals.
- Excessive consumption of calcium (>3 gm/d) may increase the risk of urinary stones and Urinary Tract Infection (UTI) and reduce the absorption of essential micronutrients.

Ca everywhere !! Which to choose ?

Types of calcium supplements

- Calcium carbonate (40% elemental calcium)
- Calcium citrate (21% elemental calcium)
- Calcium gluconate (9% elemental calcium)
- Calcium lactate (13% elemental calcium)

All types of calcium supplements are better absorbed when taken in small doses (<500 mg) & at meal times, inbetween meals.

Calcium carbonate has the best bioavailability (40% of elemental calcium). For example a 100mg tablet would provide 40 mg of absorbable calcium.

Calcium citrate has 21 % of elemental calcium. The advantage is that it can be taken between meals. It is also recommended for individuals taking acid blockers, >50 years or those who have IBS or absorption disorders. The disadvantage is that to provide the same 40mg of absorbable calcium, it has to be larger (200mg). So, calcium citrate tablets are larger & more expensive.

Calcium and Maternal Health

Calcium supplementation in pregnancy has the potential to reduce adverse pregnancy outcomes, in particular by decreasing the risk of developing hypertensive disorders during pregnancy, which are associated with a significant number of maternal deaths and considerable risk of preterm birth, the leading cause of early neonatal and infant mortality.

Preeclampsia

CALCIUM SUPPLEMENTATION IS THE FIRST, ONLY RECOMMENDED NUTRITIONAL INTERVENTION IN PREVENTION OF PRE ECLAMPSIA, IN COMMUNITIES WITH LOW DIETARY CALCIUM AND THOSE WITH OTHER INCREASED RISK FACTORS

An inverse relationship between calcium intake and hypertensive disorders of pregnancy was first described in 1980. [2] This was based on the observation that Mayan Indians in Guatemala, who traditionally soak their corn in lime before cooking, had a high calcium intake and a low incidence of preeclampsia and eclampsia. A very low prevalence of preeclampsia had been reported from Ethiopia where the diet contains



high levels of calcium.[3]

WHO recommends an intake of 1.5 – 2.0g elemental calcium / day with the total daily dosage divided into three does (Preferably taken at mealtimes) from 20 weeks gestation until the end of pregnancy. Target group includes all pregnant women, particularly those at higher risk of gestational hypertension and in areas with low calcium intake. [4]

A cohort of 524 healthy primigravidas in a tertiary care hospital in North India and observed that daily supplementation of 2 grams of elemental calcium in pregnancy was associated with 66.7% risk reduction in developing preeclampsia. This group of women had a low mean baseline calcium intake (313.83 ± 203.25 mg/day) which is lower than the recommended daily dietary intake. [5]

Imdad et al. analyzed 15 randomized control trials and showed that calcium supplementation (0.5-2gm/day) during pregnancy reduced risk of preeclampsia by 52% and that of severe preeclampsia by 25%. There was no effect on incidence of eclampsia.[6]

A Cochrane review of 13 tribals involving 15,730 pregnant women concluded that pregnant women consuming low amount of calcium (mean calcium intake <900mg /day) could reduce their risk of preeclampsia by 31-65% if they consumed an additional 1000mg of calcium each day. [7]

Low calcium intakes during pregnancy may stimulate PTH secretion, increasing intracellular calcium and smooth muscle contractibility and /or release renin from the kidney, leading to vasoconstriction and retention of sodium and fluid. These physiological changes can lead to the development of preeclampsia.

Increased levels of proinflammatory cytokines and endothelial dysfunction in preeclampsia have been implicated in stimulating osteoclast activity and hence increased bone resorption. This necessitates the supplementation of elemental calcium during pregnancies complicated with preeclampsia for preservation of maternal skeleton.[8]

Preterm Birth

Calcium supplementation has shown effectiveness in reducing the risk of preterm delivery in women with low calcium intakes. A possible mode of action of calcium is that it reduce parathyroid release and intracellular calcium and so reduce smooth muscle contractility.

A review of 11 randomized trials by Imdad et al. showed 24% reduction in preterm births following calcium supplementation in pregnancy. [9]

A study done on 524 North Indian primigravidas with low mean daily calcium intake showed a significant reduction in risk of preterm births following calcium supplementation in pregnancy. Two gram of elemental calcium was supplemented daily between 12 and 25 weeks of pregnancy, and compared with placebo group, there was a significantly lower risk of preterm delivery in the calcium group than that in control group.

Postpartum Hemorrhage

PPH is a leading cause of maternal morbidity and mortality worldwide and is caused most commonly by uterine atonicity following delivery. Calcium is a important messenger required within the uterine muscle cell to result in muscle contraction following administration of oxytocin. A physiological level of calcium is known to provide optimal contractility to normal myometrium.

Talati et al concluded that in oxytocin naïve myometrium, normocalcemia provides superior oxytocin – induced contractility compared with hypocalcemic conditions [10]

Short term bone changes

Multiparous North Indian women age 20-60 years showed decline with advancement in age indicating that pregnancy probably aggravates the bone loss in the women with faulty dietary pattern and quality.

Osteoporosis and pregnancy

Significant transplacental calcium transfer occurs during pregnancy, especially during the last trimester, to meet the demands of the rapidly mineralizing fetal skeleton. In India, a significant proportion of pregnancies occur in the early twenties, when peak bone mass is not yet achieved. [11,12] Poor pre pregnancy bone mineral density, low calcium and vitamin D intake during pregnancy and poor socioeconomic status puts these women on increased risk of low bone mass and later developing osteoporosis.

Calcium and Infant Health

Maternal calcium supplementation averaging 1300 mg /day from mid pregnancy to term, can enhance fetal

bone mineralization in women with low calcium intake.[13]

Conclusion

Significant maternal physiological changes occur to maintain calcium hemostasis during pregnancy

The mineral demands of the growing fetus are largely met by increased intestinal calcium absorption.

The daily calcium intake of pregnant women has been reported to be low. Calcium supplementation during pregnancy for women with deficient dietary calcium intake offers modest benefit in terms of preventing preeclampsia and preterm births and improving maternal and infant bone health.

Reference

1. J Obstet Gynaecol India. 2017 Oct; 67(5): 313–318. Published online 2017 May 22. doi: 10.1007/s13224-017-1007-2 Calcium: A Nutrient in Pregnancy Ashok Kumar and Simar Kaur
2. Belizan JM, Villar J. The relationship between calcium intake and edema, proteinuria, and hypertension-gestosis: an hypothesis. Am J Clin Nutr. 1980;33:2202–2210.
3. Hamlin RHJ. Prevention of pre-eclampsia. Lancet. 1962;1:864–865. doi: 10.1016/S0140-6736(62)91887-1.
4. WHO . Guideline: Calcium supplementation in pregnant women. Geneva: World Health Organization; 2013.
5. Kumar A, Devi SG, Batra S, Singh C, Shukla DK. Calcium supplementation for the prevention of pre-eclampsia. Int J Gynaecol Obstet. 2009;104(1):32–36. doi: 10.1016/j.ijgo.2008.08.027
6. Imdad A, Bhutta ZA. Effects of calcium supplementation during pregnancy on maternal, fetal and birth outcomes. Paediatr Perinat Epidemiol. 2012;26(Suppl 1):138–152. doi: 10.1111/j.1365-3016.2012.01274.
7. Hofmeyr GJ, Lawrie TA, Atallah AN, Duley L, Torloni MR. Calcium supplementation during pregnancy for preventing hypertensive disorders and related problems. Cochrane Database Syst Rev. 2014;6:CD001059.
8. Kumar A, Devi S, Prasad S, Kapoor S, Sharma S. Bone turnover in preeclampsia-complicated pregnancy in North Indian women. J Obstet Gynaecol Res. 2012;38(1):172–179. doi: 10.1111/j.1447-0756.2011.01664.x.
9. Buppasiri P, Lumbiganon P, Thinkhamrop J, Ngamjarus C, Laopaiboon M, Medley N. Calcium supplementation (other than for preventing or treating hypertension) for improving pregnancy and infant outcomes. Cochrane Database Syst Rev. 2015;(2):CD007079. doi:10.1002/14651858.CD007079
10. Talati C, Ramachandran N, Carvalho JC, Kingdom J, Balki M. The effect of extracellular calcium on oxytocin-induced contractility in naive and oxytocin-pretreated human myometrium in vitro. Anesth Analg. 2016;122(5):1498–1507. doi: 10.1213/ANE.0000000000001264.
11. Mahadevan S, Kumaravel V, Bharath R. Calcium and bone disorders in pregnancy. Indian J Endocrinol Metab. 2012;16(3):358–363. doi: 10.4103/2230-8210.95665
12. Kumar A, Mittal S, Orito S, Ishitani K, Ohta H. Impact of dietary intake, education, and physical activity on bone mineral density among North Indian women. J Bone Miner Metab. 2010;28:192–201. doi: 10.1007/s00774-009-0118-y.
13. Koo WW, Walters JC, Esterlitz J, Levine RJ, Bush AJ, Sibai B. Maternal calcium supplementation and fetal bone mineralization. Obstet Gynecol. 1999;94:577–582.



DR MALATHI G PRASAD,
MD, FRCOG(UK) DIPLOMA IN FETAL MEDICINE(FMF BARCELONA)
DR REVATHY M C CHANDRASEKARAN,
MBBS,MS(OG), ICOG FETAL MEDICINE SPECIALIST (GOLD MEDALIST)
TRICHY FETAL MEDICINE CENTRE, TRICHY.



VENTRAL CONJOINED TWINS OF THORACO-OMPHALOPAGUS TYPE - A CASE REPORT

Abstract:

This is a case report of thoraco-omphalopagus type of conjoined twin in a 28 year old G3P2L2 with Previous 2 uneventful vaginal deliveries. Both the babies are alive and healthy. No other positive family, past and personal history.No known co-morbidities. Blood group was B positive.Referred to our centre in view of suspected gastroschisis.

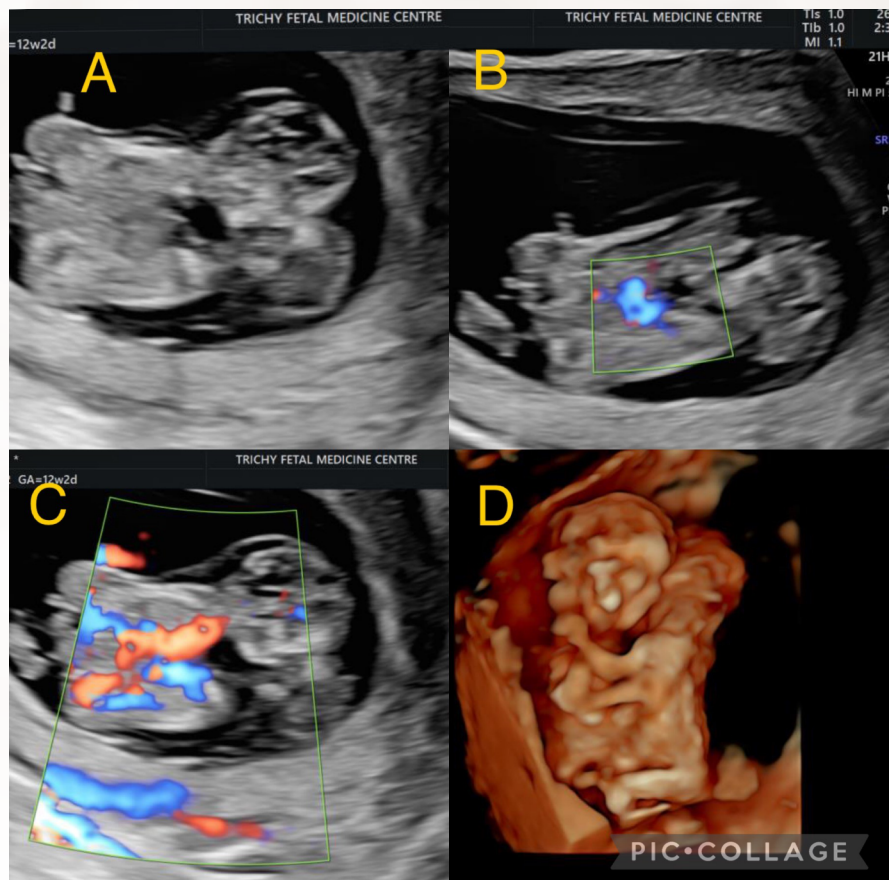
Keywords: conjoined twins; omphalopagus twins; Siamese twins; twin pregnancy ; thoracopagus twins ; thoraco-omphalopagus twins.

Introduction:

One of the rare form of twin gestation is conjoined twin which is associated with high perinatal mortality and morbidity. Popularly called as Siamese twins, is a result of abnormal embryogenesis. Incomplete cell division between the 13th and 15th days after fertilisation has been proposed to be the pathogenesis of conjoined twin formation. They are classified based upon the site of attachment. It is estimated to occur in approximately. 1 in 250000 live births². Based on the site of the attachment, conjoined twins could be ventral in 87% of the cases and dorsal in 13% of the cases. Ventral unions are classified to the thorax (thoracopagus-19%), abdomen (omphalopagus-18%) and pelvis (ischiopagus-11%). Dorsal unions include skull(craniopagus-5%),sacrum (pygopagus - 6%) or back (rachipagus)¹⁴. Most conjoined twins are proposed to be female in predominance¹².

Case report:

28 year old G3P2L2 , with two previous vaginal delivery and alive,healthy babies was referred to our fetal medicine unit in view of ultrasonography done at 13 weeks showing suspicion of gastroschisis. Detailed history taking revealed no positive relevant past, family, personal and medical history. Her general physical examination including abdomen, thyroid, breast turned out to be normal. Her blood pressure, complete blood count, thyroid profile, glucose tolerant test were within normal limits.



An ultrasound examination was done trans-abdominally which revealed a grossly abnormal fetus. We could see a conjoined twin. Each foetus having single head and a pair of arms and legs. The twins were joined at lower chest and upper abdomen. One functional heart was observed centrally between both foetuses. Doppler study showed two aortic arch from the centrally placed heart to each foetus. There was two umbilical cord with single posterior placenta. Liquor was normal. 3 dimensional picture confirmed attachment of two fetuses in lower thorax and upper abdomen region. Hence a diagnosis of ventral conjoined twin of thoracomphalophagus type was made.

Detailed counselling was given to the expectant parents and they were informed in detail about the malformation. Discussed regarding the poor prognosis of both the fetus and high perinatal mortality, morbidity, surgical separation and its associated mortality, morbidity and success rate. Chances of obstructed labour and possibility of cesarean section if they wish to continue. Adequate time and information was given to the expected couple and their extended family. The couple and their family decided to terminate the pregnancy and deferred fetal autopsy.

Discussion:

Conjoined twins are twins who are fused physically in utero and consequently at birth. The pathophysiology is when a monozygotic twin pregnancy cleaves more than 13 days after fertilisation¹². Conjoined twins are monochorionic and monoamniotic. Incidence being one in 50,000 to 2,00,000 pregnancies with a stillbirth rate of around 60%¹³. Other than diabetes mellitus no risk factors was proposed in literature so far. Female sex predominance with female to male sex ratio of 3:112.

Adequate knowledge about this rare twin pregnancy could help the parents have a better understanding and prepare them in the decision making regarding the pregnancy. The overall survival rate of conjoined twins is from 5-25%¹⁴.

The care for conjoined twins starts at first booking visit in the antenatal clinic where the diagnosis can be made as early as 10 weeks by imaging modality⁶. Differential diagnosis includes cystic hygroma, teratoma, lymphangioma, omphalocele, gastroschisis, bladder exstrophy body wall defect etc.,. Prenatal MRI and 3D imaging technique add additional values to the

diagnosis and further management¹. Early referral and counselling is needed based on the extent of fusion and the functioning organ.

Conjoined twins with especially cardiac abnormalities (mostly thoracopagus twins) carry poor prognosis and considered ineligible for surgical separation and hence is not suitable for continuation of pregnancy⁸. It is clinically important to decide termination at an early gestational age as late-stage termination is fraught with problems.

Conjoined twins who made till birth are categorised based on whether they are surgically separable or not. Twins who share vital organs are considered to be high risk for separation since it causes death of one or both the twin. This presents ethical confusion and the decision finally lies with the parents.

Surgical separation should be followed by atleast one simulation of separation event. Special care during medical management should be taken due to the pharmacokinetic consideration.

Conjoined twins generally have a poor prognosis. The total survival rate is around 5 - 7.5%⁷. Survival rate after surgical separation is around 60%⁷. Antenatal imaging, postnatal surgery if applicable, use of tissue expansion in surgery, and cadaveric transplant for vital organs that are shared between the twins, might lead to a better prognosis. Surgery related complications such as organ failure, skin defects, surgical infection, bleeding, injury to internal organs and/or vasculature, and failure to complete the procedure can happen which should be included in the counselling¹⁶.

Educating and enlightening the patients regarding the challenges faced with conjoined twins and the poor prognosis can help the family in decision making regarding the pregnancy. To enhance the outcome, any conjoined twin pregnancy is categorised into the following for better counselling and prognostication¹⁵,

- Those who do not survive in-utero
- Those who survive pregnancy but fail to survive past infancy
- Those who survive infancy but surgically inseparable
- Those who survive infancy and are surgically separable

Obstetric consideration includes materno-fetal medicine specialist consultation and follow-up,



cesarean section considered as obstructed labour and stillbirth common with vaginal delivery.

Multidisciplinary medical team, prenatal counselling regarding nature of management and prognosis can make decisions regarding surgical treatment and palliative care. Nursing care (maternal) considerations including privacy, grief counselling and providing emotional support to the patient and family.

Ethical approval about publication:

Ethical approval not required. The patient's permission was obtained.

Disclosure of funding: None

Conflict of Interest:

No potential conflict of interest relevant to this article was reported.

Authors contribution:

Data gathering: Malathi G prasad, Trichy fetal medicine centre, trichy.

Writing manuscript: Revathy M C, Trichy fetal medicine centre, trichy.

Editing and approval of final draft: Malathi G prasad, Revathy M C

Approval of final draft: Malathi G prasad, Revathy M C

References:

1. Mathew RP, Francis S, Basti RS, Suresh HB, Rajarathnam A, Cunha PD, et al. Conjoined twins- role of imaging and recent advances. *Journal of Ultrasonography*. 2017; 17(71): 259. <https://doi.org/10.15557/JoU.2017.0038>
2. Spitz L, Kiely E, Pierro A. Conjoined twins. *Rickham's Neonatal Surgery*: Springer; 2018. p. 457-74. https://doi.org/10.1007/978-1-4471-4721-3_19
3. Conjoined twins separated in Malaysia. *The Telegraph*. 2012[cited 2020 Jan 30]. Available from <https://www.telegraph.co.uk/news/worldnews/asia/malay-sia/9434206/Conjoined-twins-separated-in-Malaysia.html>
4. Afroze, S., Mannan, M., Dey, S., Moni, S., Shabuj, M. K., Jahan, I., et al. Risk Factors and Complications of Newborns with Birth Defect: A Hospital based Case- Control Study. *Bangladesh Journal of Medical Science*, 19(1), 2019. 133-140. <https://doi.org/10.3329/bjms.v19i1.43886>
5. Ahmed Mohammed Samy El-Agwany and Tamer Mamdouh Abdeldayem. "Thoraco-Omphalopagus: A Case of Conjoined Twin with a Single Heart". *EC Gynaecology* 2016;2(3):203-7.
6. Chiabi A, Nkemayim D, Tchokoteu P-F, Guegang EG, Ngoh NN, Minkande JZ, et al. Conjoined twins in Cameroon: issues inherent in diagnosis and management in the African context: case report. *African Journal of Reproductive Health*. 2009;13(3):127-35.
7. Brizot M, Liao AW, Lopes LM, Okumura M, Marques MS, Krebs V, et al. Conjoined twins pregnancies: experience with 36 cases from a single center. *Prenatal diagnosis*. 2011;31(12):1120-5. <https://doi.org/10.1002/pd.2843>
8. Sultan OM, Tawfeek AS. Conjoined twins- thoraco-omphalopagus (type A). *BJR Case Rep*. 2015;2(1):20150016. <https://doi.org/10.1259/bjrcr.20150016>
9. Malaysian Penal Code, Act 574, Section 312, (revised 2018).
10. Savulescu J, Persson I. Conjoined Twins: Philosophical Problems and Ethical Challenges. *The Journal of Medicine and Philosophy*. 2016; 41(1): 41-55. <https://doi.org/10.1093/jmp/jhv037>
11. Patil PS, Kothari P, Gupta A, Kekre G, Dikshit KV, Kamble R, et al. Successful Separation of Omphalopagus Twins: A Case Report. *Journal of Neonatal Surgery*. 2016;5(1):5.
12. Mian A, Gabra NI, Sharma T, Topale N, Gielecki J, Tubbs RS, Loukas M. Conjoined twins: From conception to separation, a review. *Clin Anat*. 2017 Apr;30(3):385-396. [PubMed]
13. De Ugarte DA, Boechat MI, Shaw WW, Laks H, Williams H, Atkinson JB. Parasitic omphalopagus complicated by omphalocele and congenital heart disease. *J Pediatr Surg*. 2002 Sep;37(9):1357-8.
14. Kaufman MH. The embryology of conjoined twins. *Childs Nerv Syst*. 2004 Aug;20(8-9):508-25.
15. Harper RG, Kenigsberg K, Sia CG, Horn D, Stern D, Bongiovi V. Xiphopagus conjoined twins: a 300-year review of the obstetric, morphopathologic, neonatal, and surgical parameters. *Am J Obstet Gynecol*. 1980 Jul 01;137(5):617-29.
16. Fallon SC, Olutoye OO. The surgical principles of conjoined twin separation. *Semin Perinatol*. 2018 Oct;42(6):386-392.



DR. VICTORIA JOHNSTON M.D, F.I.C.S, F.I.C.O.G
JANET NURSING HOME, TRICHY

ACUTE PANCREATITIS IN PREGNANCY

Introduction:

Acute pancreatitis (AP) in pregnancy is a challenging clinical problem to manage, occurring in approximately 3 out of 10,000 pregnancies. The spectrum of AP in pregnancy ranges from mild pancreatitis to severe pancreatitis associated with necrosis, abscesses, pseudocysts and multiple organ dysfunction syndromes.

We present here a case of Acute Pancreatitis in Pregnancy

- Mrs. NB, 21 years Primi
- C/o excessive vomiting since 2 days
- C/o severe right upper abdominal pain of 2 days duration
- H/o admission elsewhere for similar complaints 10 days back
- Past H/o evaluation for jaundice at 18 yrs of age
- O/E Not anaemic, no pedal edema, not jaundiced
- P/A soft
- P/V Uterus AV, 10-12 weeks size, os closed

Course of disease:

Patient did not respond to routine intravenous hydration, antiemetics and analgesics for the first 24 hrs, her pain got aggravated hence, further evaluation was done.

Investigations

Routine antenatal investigations including blood sugar, haemoglobin and thyroid

function tests were normal

Urine ketone was positive.

Lipase and amylase levels were grossly elevated.

Normal range:

INVESTIGATION	31/05/2023	02/06/2023	05/06/2023	09/06/2023
AMYLASE U/L	321	385	710	630
LIPASE U/L	616	857.7	1325.5	1272

Serum amylase – 28-100 U/L

Serum lipase – 13–60 U/L

Her serum albumin, calcium, CRP, liver function test and lipid profile were normal

USG/MRI – Abdomen and pelvis: 31 /05/2023

No CBD/ GB calculus

Liver, gall bladder, spleen, pancreas, both kidneys, urinary bladder and ovaries appear normal

No biliary dilatation

No evidence of enlarged iliac/ paraaortic nodes

No ascites

Viable intrauterine pregnancy of 8 to 9 weeks

Treatment and outcome:

She was kept nil oral by mouth, bowel rest, on intravenous hydration & nasogastric tube suction. Antibiotics were given (.Meropenem 1 gm IV 8th hourly)

Inj. Ulinastatin (Trypsin inhibitor) 100,000 U IV bd

We had got the opinion of general surgeon, physician and medical gastroenterologist.

Patient developed electrolyte disturbances such as



hypokalemia and metabolic acidosis which were corrected with KCL and Na HCO₃.

Patient had a prolonged course and became symptomatically better after 21 days of treatment

NT scan done on 30/06/2023 showed viable 12 weeks fetus with megacystis bladder due to posterior urethral valve syndrome hence, termination of pregnancy was advised and done on 01/07/2023

POC were sent for karyotyping.

Discussion:

Acute pancreatitis is a rare and serious complication during pregnancy. Pregnancy related haematological and biochemical alterations influence the interpretation of diagnostic tests and assessment of severity of AP. As in any other disease associated with pregnancy, AP is associated with greater concerns as it deals with two lives rather than just one. When properly managed AP in pregnancy does not carry a dismal prognosis as in the past.

The most frequent etiology of acute pancreatitis in pregnancy is biliary caused by gallstones or sludge; other causes are hyperlipidemia, hypertriglyceridemia, hyperparathyroidism, congenital ductal anomalies, recent ERCP, alcohol abuse and rarely autoimmune pancreatitis. Non-biliary pancreatitis may be associated with connective tissue diseases, abdominal surgery, infections (viral, bacterial or parasitic), blunt abdominal injuries or could be iatrogenic caused by medications (diuretics, antibiotics, antihypertensive drugs). Certain metabolic conditions including acute AFLP and familial hypertriglyceridemia, also predispose to pancreatitis, cases of acute and chronic pancreatitis have been linked to numerous mutation of the cystic fibrosis transmembrane conductance regulator gene.

Clinical features:

Signs and symptoms of acute pancreatitis usually include incapacitating mid-epigastric pain, left upper quadrant pain radiating to the left flank, anorexia, nausea, vomiting, dyspepsia, decreased bowel sounds, low-grade fever, and associated pulmonary findings 10% of the time (unknown cause). They have tachycardia, hypotension, fatty food intolerance and abdominal tenderness.

The most common misdiagnosis of pancreatitis in the

first trimester is hyperemesis. In women presenting with severe nausea and vomiting in the first trimester, consider obtaining amylase, lipase levels, and liver function tests, which when elevated are diagnostic of pancreatitis.

The symptoms include abdominal pain (colicky or stabbing) which may radiate to the right flank, scapula and shoulder. Onset of pain is rapid, with maximal intensity in 10 to 20 minutes. Pain is steady and moderate to severe. Band-like radiation of the pain to the back occurs in 50% patients

As many as 10% have sepsis which causes endothelial activation and can lead to acute respiratory distress syndrome.

Physical examination:

Physical findings vary with the severity of illness, in moderate to severe pancreatitis the patient appears acutely ill and is found lying in the "fetal position" with flexed knees, hips and trunk. Abdominal tenderness is often found; in diffuse peritonitis muscle rigidity can be present. Bowel sounds, secondary to paralytic ileus, is usually hypoactive or absent. In severe pancreatitis the general physical examination may reveal abnormal vital signs if there are third-space fluid losses and systemic toxicity. Due to hypovolemia, tachycardia up to 150 /min and low blood pressure could be found. Also, because of severe retroperitoneal inflammatory process temperature may increase. Dyspnea, tachypnea and shallow respirations resulting in hypoxemia may be present.

Altered maternal acid-base status can adversely affect fetal acid-base status. Acute fetal hypoxia activates some compensatory mechanisms for redistribution of blood that enable fetus to achieve a constancy of oxygen consumption in the fetal cerebral circulation and in fetal myocardium. Redistribution of blood to vital organs enable fetus to survive for moderately long period of limited oxygen supply, but during more severe or sustained hypoxemia, these responses were no longer maintained and decompensation with fetal tissue damage and even fetal death may occur.

Some physical findings point to a specific cause of acute pancreatitis: jaundice in biliary origin, spider angiomas in alcoholic or xanthomas and lipemia retinalis in hyperlipidemic pancreatitis.

Laboratory diagnosis:

Laboratory investigations are the same as in non-pregnant and rely on at least a three- fold elevation of serum amylase and lipase level in the blood. The total serum amylase level rises within 6 to 12 hours of onset of the disease, usually remain elevated for three to five days. In 173 pregnant women with pancreatitis, the mean amylase value was 2000 IU/L and the mean lipase value was 3000 IU/L

Importantly the degree of enzyme elevation and disease severity do not reliably correlate. Leucocytosis is usually found and 25% of patient have hypocalcemia, elevated serum bilirubin and aspartate transaminase levels may signify concomitant gall stone disease

Imaging methods:

Imaging in pregnancy remains a controversial issue with concern for the effects of radiation on the developing fetus. Abdominal ultrasound (US) is the ideal imaging technique for detection of dilated pancreatic ducts and pseudocysts and focal accumulations larger than 2 to 3 cm. US has no radiation risk to the fetus, but is limited by operator skill, patient obesity and bowel dilatation. Computed tomography (CT) should be avoided, especially during the first trimester, because of radiation exposure to the fetus. Endoscopic US and MRI may be done when benefits outweigh the risks.

Treatment:**Conventional treatment measures:**

The initial management of acute pancreatitis during pregnancy is similar to management in non-pregnant patients. Treatment consists of fluid restoration, oxygen, analgesics, anti-emetics and monitoring of vital signs. Important additional measures during pregnancy include fetal monitoring, attention to the choice of medications and positioning of the mother to avoid inferior vena cava constriction.

Mild pancreatitis treated conservatively usually resolves within 7 days. Ten percent of patients have severe course, and they are best managed in an intensive care unit. The third space fluid sequestration is the most serious hemodynamic disorder leading to hypovolemia and organ hypoperfusion resulting in multiple organ failure. In volume- depleted patients

the essential treatment modality is initial infusion of 500 to 1000 ml of fluid per hour. Monitoring of hydration, cardiovascular, renal and respiratory functions is important for early detection of volume overload and electrolyte disturbances.

Prophylactic use of antibiotics is very controversial and the choice of antibiotic in pregnancy is difficult. There are concerns with regard to the antibiotic being transplacentally transferred to the fetus with a risk of teratogenicity. Antibiotics have no role in the treatment of mild acute pancreatitis.

If bacterial superinfection, necrotizing pancreatitis, sepsis, or cholangitis is found, broad spectrum antimicrobials are administered. If common duct stones are found, ERCP is indicated.

Many pharmacological agents (somatostatin, octreotide, n-acetyl-cysteine and probiotics) have been investigated in acute pancreatitis, but because most of them have failed to show a positive effect they should be avoided in pregnancy.

Cessation of oral feeding has been thought to suppress the exocrine function of pancreas, and to prevent further pancreatic autodigestion. Bowel rest is associated with increased infectious complications, total parenteral nutrition (TPN) and enteral nutrition (EN) have an important role in the management of acute pancreatitis. Keeping the patients "nil by mouth" with the use of TPN has been for years a traditional treatment of acute pancreatitis. EN is physiological, helps the gut flora maintain the gut mucosal immunity, reduced translocation of bacteria, while simultaneously avoiding all the risks of TPN.

Mild cases of acute pancreatitis do not need nutritional support, as the clinical course is usually uncomplicated and a low-fat diet can be started within 3 to 5 days.

Treatment of severe necrotizing pancreatitis should include enteral feeding by nasojejunal tube and if needed, should be supplemented by parenteral nutrition.

Surgical treatment:

Surgical treatment of pancreatitis has two aspects, which include operative intervention for the disease itself and surgical management of associated biliary tract disease once acute inflammation subsides.

Surgical treatment carries risk to the fetus from surgery and anaesthesia and risk specific to laparoscopic



surgery. Laparoscopic cholecystectomy (once considered contraindicated during pregnancy) is today, probably, the best treatment for the patients who fail to respond to conservative management or because of recurrent episodes. Benefits of laparoscopy during pregnancy appear similar to those non-pregnant patients including less postoperative pain, less postoperative ileus, significantly reduced hospitalization, and decreased narcotic use and quick return to a regular diet and faster recovery. Other advantages of laparoscopy includes less manipulation of the uterus and detection of other pathology that may be present and because of early mobility reduced risk of postoperative deep vein thrombosis. Cholecystectomy is considered safe at all stages of pregnancy and may be performed in any trimester of pregnancy without any increased risk to the mother or fetus. Early cholecystectomy should be performed in patients with mild acute biliary pancreatitis while patients with SABP should undergo this procedure within 4 and 6 weeks, respectively, after hospital discharge

Outcome:

Prognosis for women with mild disease who respond to conservative management is excellent for mother and fetus. However, for more severe form of disease, maternal mortality and fetal morbidity and mortality rates increase. In the past decades, high perinatal mortality rate, up to 50% secondary to acute pancreatitis resulted from neonatal deaths after preterm delivery, but improvements in neonatal intensive and supportive care have reduced this rate. The mechanisms of demise include, also, placental abruption and profound metabolic disturbance, including acidosis. This highlights the importance of regular fetal monitoring and consideration of delivery if, the maternal disease is deteriorating.

In one review of 101 pancreatitis patients, Eddy and coworkers (2008) found 30% preterm delivery rate and 11% were delivered before 35 weeks gestation

There were also 4% still births

There were 2 pancreatitis related maternal deaths, importantly almost a third of women had recurrent pancreatitis during pregnancy.

Conclusion:

Acute pancreatitis is a rare entity in pregnancy. Diagnosis is based on clinical presentation, laboratory investigations and imaging methods performed with precaution because of potential radiation risk of the fetus.

General management of mild AP in pregnancy is conservative and supportive, while severe AP deserves hospitalization in intensive care unit and endoscopic or surgical intervention. Although treatment of acute pancreatitis during pregnancy is similar to general approach in acute pancreatitis patients, a multidisciplinary team consisting of gastroenterologist, gastro-intestinal surgeon, radiologist and obstetrician should be included in the treatment and follow up of these patients.

References:

1. William's textbook of Obstetrics 26th edition, chapter 55: Hepatic, Biliary, and Pancreatic disorders.
2. Pitchumoni CS, Yegneswaran B. Acute pancreatitis in pregnancy. *World J Gastroenterol.* 2009; 15:5641–6.
3. Ramin KD, Ramsey PS. Disease of the gallbladder and pancreas in pregnancy. *Obstet Gynecol Clin North Am.* 2001;28:571–80
4. Wilkinson EJ. Acute pancreatitis in pregnancy: A review of 98 cases and a report of 8 new cases. *Obstet Gynecol Surv.* 1973;28:281–303
5. Corlett RC, Jr, Mishell DR., Jr Pancreatitis in pregnancy. *Am J Obstet Gynecol.* 1972; 113:281–90.
6. Montgomery WH, Miller FC. Pancreatitis and pregnancy. *Obstet Gynecol.* 1970; 35:658–64.
7. Scott LD. Gallstone disease and pancreatitis in pregnancy. *Gastroenterol Clin North Am.* 1992; 21:803–15.



OUR SERVICES

Obstetrics:

Most advanced equipment in hands of highly qualified doctors to ensure expectant mother enjoys her pregnancy journey even in high risk pregnancies.

Ultrasound:

- Dating scan
- NT scan
- Early Target scan
- Anomaly scan
- Growth scan & Doppler
- Fetal echo

Genetic counselling

- Pre-pregnancy counselling
- Antenatal Counselling
- Evaluation of index child.

Prenatal Testing

- First trimester screening
- Quadruple screening test
- Non invasive screening

Perinatal pathology

- Perinatal & placental evaluation

Fetal interventions

- Amniocentesis
- Chorionic villous sampling
- Multi fetal reduction

First Centre In PERAMBALUR To Deploy Ge Voluson E8 !!

Dr. SIDHARTHAN .S

M.B.B.S.,M.D.R.D.,F.A.OG.S.,
Consultant Radiologist and
Fetal Medicine Specialist
+91 91597 91930

Dr. S. UMMAR BASHA

M.B.B.S.,M.D.R.D.,F.I.F.O.R
Consultant Onco-Radiologist &
Fetal Imaging Specialist
+91 75983 85227



www.kyprosscan.com

Comprehensive Diagnostic Laboratory Practices Covering

- Biochemistry
- Immunology
- Hematology
- Clinical Pathology
- Microbiology
- Molecular Biology
- Genetics
- Serology
- Virology
- Mycology

HIGHLIGHTS

- Premium end scan machine
- Same day appointment*
- Ethical effective practice
- Radiologist with fetal expertise

*Maximum effort will be given



11/47F/21, Vengatesapuram, Near Star Saw Mill, Perambalur. Ph : 9 914 913 912 | 72 9500 9600

Angiographic 4D
CT Scan
500 SLICE HD
Diagnostic & Therapeutic Interventions



High Definition
1.5T MRI
Optics Powered

2D / 3D / 4D
ULTRASONOGRAM
& DOPPLER
Diagnostic & Therapeutic Interventions



MASTER HEALTH
CHECKUP PACKAGES

DIGITAL
MAMMOGRAM
& BIOPSY

ENDOBONCHIAL
Ultrasonogram & Biopsy

ECHOCARDIOGRAPHY
ECG & TMT
EEG & ENMG
PFT

X-RAY
HIGH FREQUENCY
Computed Radiography
Contrast Studies

HISTOPATHOLOGY | BIOCHEMISTRY | MICROBIOLOGY
CYTOLOGY | IMMUNOLOGY | MOLECULAR BIOLOGY
IMMUNOHISTOCHEMISTRY | HEMATOLOGY

9/10, Thillai Nagar 11th cross East, (Ramachandrapuram),
Near Sarathambal Temple, Theanur, Trichy - 620 017
0431 4028888 +91 89400 08888, +91 9159668888.
www.magnumimaging.in





**DR. LAKSHMI PRABHA MBBS., DGO., DNB. (OG), F.I.C.O.G
RANA HOSPITAL, TRICHY**

MATERNAL CONGENITAL COMPLETE HEART BLOCK IN PREGNANCY A RARE CASE REPORT.

Introduction

Complete heart block is a conduction disorder characterized by a random relationship between the atrial and the ventricular activation where the atrial impulses are not conducted to the ventricle. The incidence of complete heart block Congenital Heart Block (CHB) is estimated to be 1 in 15,000 to 20,000 live births. It may be congenital or acquired. The acquired variety is rare during pregnancy as this type is mostly seen after 50 years of age. However, the congenital variety is seen during pregnancy but that is also very rare and only few cases have been reported in the literature.

Whenever encountered in a pregnant women, Congenital Heart Block CHB presents a challenge for the obstetrician and calls for a multidisciplinary approach involving the cardiologist and anesthesiologist.

Mrs. V 35 married recently presented to AN OPD. Routine early Pregnancy work up was done. On early USG she had single intra Uterine viable pregnancy with 6 weeks of gestation with intramural fibroid in left lateral part of fudus measuring 7X6cm. On routine auscultation she had continuous murmur in left 4th ICS. Hence cardiologist opinion obtained On ECG she had complete heart block had a heart rate of 46-48 beats per minute. Antenatal period was uneventful without syncopal attacks or breathlessness.

ECHO Normal.

B.P 140/90 hence started on Calcium Channel Blocker avoiding labetalol. She was given progesterone support to prevent preterm labour (fibroid). At 20 weeks Fetal echo was done to R/o CHD for fetus. Anomaly scan was normal. Her Anti-Hypertensive (AHT) was increased stepped with Hydralazine and B.P controlled. Prophylactic steroids given at 30 weeks. Her B.P was controlled with AHT. Since she had unfavorable

cervix She opted for elective LSCS.

She delivered an alive male baby weighing 3kg at 38 weeks under spinal anesthesia. She had fibroid near the left cornual end which was not disturbed during LSCS uterotonics given to prevent PPH. Post operatively she was moved to ICU and Monitored. Her BP stabilized with minimal AHT. Her Heart rate continued to be 46-48/mt. Her post-operative period was uneventful. She was discharged on Fifth Post op day. Cardiologist opinion to opt for pace maker at a later period was given.

Discussion

The incidence of CHB is around 1:15,000 to 1:20,000. CHB is usually asymptomatic without any specific problems during pregnancy. The patient reported here also did not have any symptoms during the antenatal period, and no pregnancy-related complication was seen. No other complication like oligohydramnios or IUGR was seen in our case; There are different opinions regarding the need for pacemaker during pregnancy. Modi et al. Favoured managing asymptomatic patients without pacemaker with emergency arrangements for pacing available. Hidaka et al. suggested that pacemaker is not routinely required during labor in patients with AV block. Khardke et al. recommended that temporary pacing should be done in patients with atropine-resistant bradycardia, first- and second-degree AV block and atrial fibrillation with low ventricular rate. Similarly, there is no definite recommendation regarding permanent pacing; however, some authors have suggested it to be done early in pregnancy as syncopal attacks could be life threatening and pacing may significantly reduce morbidity and mortality. Due to the sudden onset high sympathetic blockade spinal anesthesia often results in bradycardia which may be devastating for the patients with CHB. For this reason, use of incremental

epidural or low-dose combined spinal and epidural has been recommended by most of the authors for any instrumental delivery or cesarean section.

Emergency resuscitative measures may be needed any time. To tackle such type of emergency, a complete team with an interventional cardiologist, anesthesiologist and gynecologist must be available all the time. Such patients should always be managed at well-equipped centers with intensive care facilities.

Interventional cardiologist should be available. As the patients are at risk of mortality due to unpredictable syncope, emergency resuscitative measures should always be at hand with an interventional cardiologist present all the time as bradycardia unresponsive to drugs will need immediate pacing. This is particularly important at the time of labor when the cardiac demands are more and the patient is more prone to develop syncopal attacks due to slowing of heart rate associated with Valsalva maneuver.

Drugs indicated should be ready, and drugs contraindicated should be kept away. While managing such patients, particular attention should be given as to what drugs can aggravate the heart block and should be kept away from the patient. Drugs like labetalol (for preeclampsia) and nifedipine (for preterm labor) which are commonly used otherwise are contraindicated and should be kept away. If general anesthesia is planned in such patients, then drugs with least depressing effect on the heart should be preferred like ketamine for induction of anesthesia. Agents like fentanyl and suxamethonium have been reported to cause bradycardia and asystole. So should be avoided. Drugs needed to increase the heart rate during sudden fall in rate or syncopal attack like atropine and isoproterenol should be kept at hand.

Discussion

Several physiological changes in cardiovascular system occur during pregnancy to meet the increased demands. There is rise in circulatory blood volume, stroke volume, heart rate and a fall in systemic vascular resistance during pregnancy. In CHB heart rate fails to increase and may lead to decompensation particularly during intrapartum and postpartum period. There can be distension of all four cardiac chambers, atria being thin walled are affected most. Thaman et al hypothesise that increased atrial wall stress and structural remodelling can result in increased irritability and conduction delay of atrial musculature.

This may result in development of new atrial arrhythmia, unmasking of subclinical conduction abnormality and worsening of clinically evident bradyarrhythmias including different grades of heart block.

The finding of CHB in pregnancy is rare, if present it is usually congenital. In fact, 30% of the cases of congenital CHB (CCHB) remain undiscovered until adulthood and may therefore present during pregnancy for the first time. Acquired heart block during pregnancy is very rare and may be due to myocarditis, collagen vascular diseases like systemic lupus erythematosus, following infective endocarditis of aortic valve with root abscess or as a complication of cardiac surgery. In acquired heart block, block is distal to AV node, heart rate is usually 40 or less per minute with wide QRS in ECG. They are usually symptomatic in the form of blackout, presyncope or syncope. CCHB can occur as isolated condition or along with other congenital heart disease. Isolated CCHB is relatively benign, compatible with normal pregnancy, and there may be increase in heart rate with exercise, atropine or sympathomimetics like orciprenaline as the block is in AV node in such cases. Some patients with CCHB may experience dyspnoea, syncope and Stokes-Adams attacks.

Symptoms are common in late months of pregnancy, during labour or immediate post partum. During second stage of labour Valsalva during bearing down stimulates vagus nerve and may cause dangerous bradycardia, asystole and cardiac arrest. Syncope and cardiac arrest have been reported in postpartum period also.

Pregnancy outcome

Asymptomatic CHB without organic heart disease usually have favourable pregnancy outcome. However intrauterine growth restriction (IUGR) and preterm birth has been reported in few patients. Our patient did not have any pregnancy-related complications.

Delivery options

There are no definite guidelines for the management of such patients. Vaginal delivery is not contraindicated, caesarean section is reserved for obstetric indications. Patients with CCHB if asymptomatic, with narrow complex in ECG, ventricular rate (heart rate) between 40 and 60 and there is rise in heart rate with exercise or atropine;



usually tolerate the pregnancy and delivery without any unfavourable events.

Indications for pacing

A pacemaker is indicated if there is history of syncope, wide QRS complex, very low heart rate (less than 40/min), QT prolongation, ventricular dysfunction and heart failure. Permanent pacemaker can be implanted at any stage of pregnancy. Short-term temporary pacing may be required during labour and delivery. In earlier days, temporary pacemaker was used routinely in such patients probably to withstand any haemodynamic alterations. It was seen that many of them did not require pacing and the procedure is not without risk. There can be pacemaker-related radiation exposure, bleeding, embolism, right ventricular perforation, infection or pacemaker malfunction. 2018 European Society of Cardiology Guidelines states that isolated CCHB has a favourable outcome during pregnancy especially with narrow QRS. Temporary pacemaker is unnecessary in stable patients but recommended in selected women with symptoms due to bradycardia and syncope.

Approach to monitoring

Preconceptional counselling—pregnant woman with CHB and her family members should be counselled for pacemaker implantation, if required during pregnancy.

Antenatal

Patient should be asked about head reeling, blackout, syncopal attack and shortness of breath on exertion during her antenatal visit. If such symptoms are there cardiological re-evaluation should be done for readjustment of drugs or need of pacemaker.

Intrapartum

Labour should be monitored and adequate analgesia should be given. Continuous ECG monitoring should be done to detect any life-threatening bradycardia. Instrumental delivery is advocated to cut short the second stage of labour and to avoid bearing down by the woman. LSCS is done only for obstetric indications. Isoprenaline infusion should be kept stand-by. Femoral/jugular venous access may be secured for emergency transvenous temporary pacing, if required.

In the centre, where transcutaneous temporary pacing is available pacing pads should be attached to the

chest wall of the woman, so that immediate pacemaker can be given if required. It will avoid the transfer of patient to catheterisation laboratory.

Post partum

Patient should be monitored in the postpartum period as there is chance of symptomatic bradycardia.

If a temporary pacemaker has been given it has to be removed under the coverage of isoprenaline infusion to avoid the possibility of asystole and cardiac arrest. Such patients may require permanent pacemaker later on and should be followed up.

Contraception

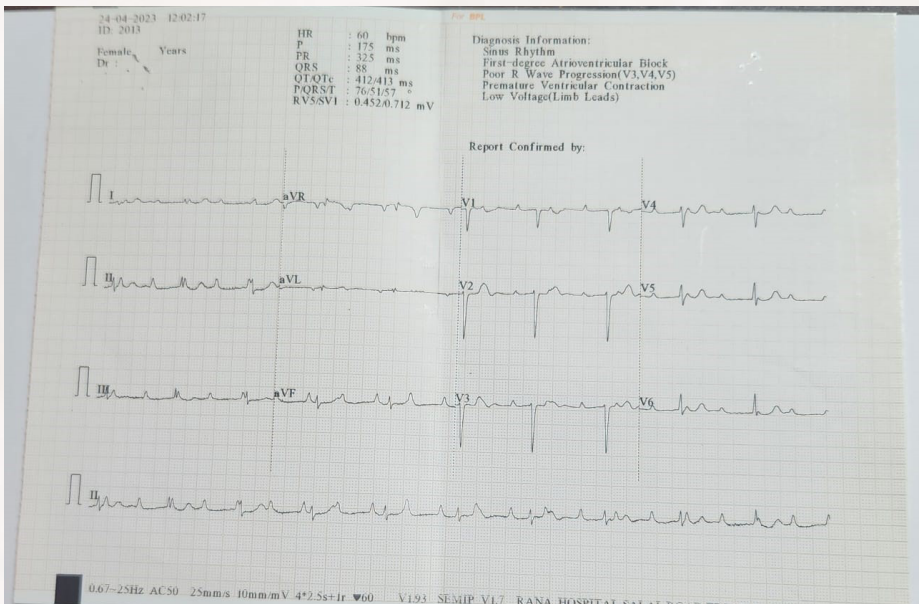
Cafeteria approach with a basket of choices of family planning methods should be offered to the patient as there is no contraindication to any method.

Anaesthetic consideration

There is no clear guideline as regards the appropriate anaesthesia technique in women with CHB undergoing LSCS. Goal is to maintain the haemodynamic stability, technique and drugs chosen should have minimal effect on heart rate. Spinal, epidural and general anaesthesia, with or without temporary pacemaker has been reported in case reports. Regional anaesthesia is safe in such situation, as a stable haemodynamic status can be obtained by titrating intravascular volume and phenylephrine infusion guided by continuous invasive monitoring. Most authors recommend incremental epidural or low-dose combined spinal and epidural anaesthesia for any instrumental delivery or caesarean section. Our patient underwent caesarean section under spinal anaesthesia without temporary pacemaker support. We did not encounter any haemodynamic instability probably due to adequate (750 mL) preloading of intravenous fluid. The baby was 3 kg with normal APGAR score and without any neonatal heart block or structural heart disease.

Conclusion

CHB in pregnancy is rare and it is mostly congenital. One of the common investigation ECG can diagnose CHB. Management of such a grave condition need multidisciplinary team approach. Detailed cardiological evaluation with echocardiography (ECHO) and holter is to be done. Resting pulse rate between 40 and 60, narrow QRS complex in ECG and



Learning points

Do not forget to palpate and count the pulse. Proper examination gives simple clue to diagnosis and helps preventing future life-threatening adverse events. If pulse rate is less than 60/min do ECG and take opinion of cardiologist.

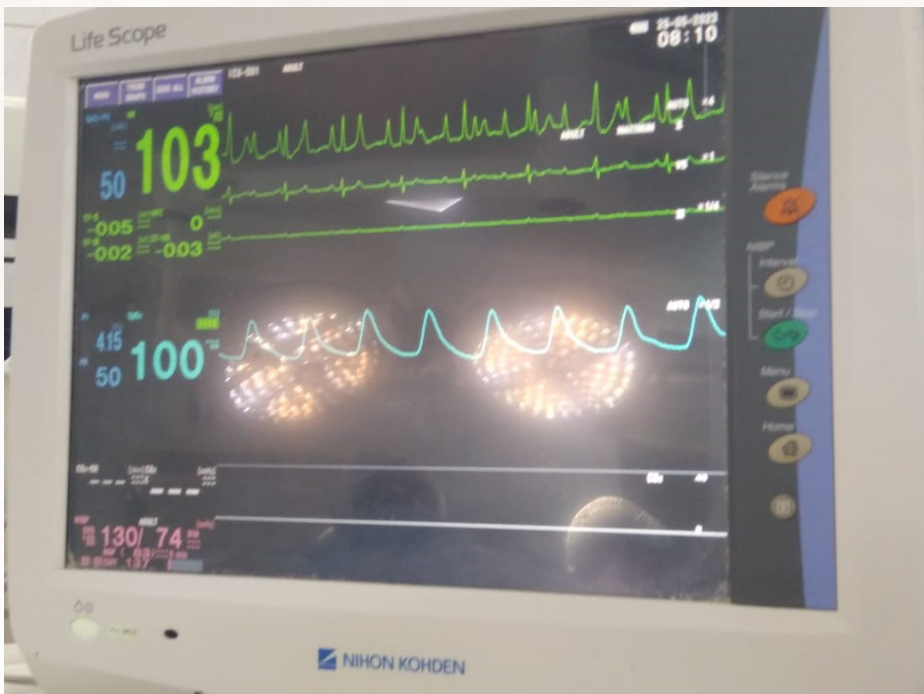Avoid labetalol and other beta blockers like atenolol, metoprolol and so on which may further decrease the heart rate.

Avoid anaesthetic drugs like prostigmine, fentanyl and suxamethonium which can cause bradycardia and asystole.

positive chronotropic response to exercise or atropine in an asymptomatic woman predict a benign course, with uneventful labour and delivery. Vaginal delivery is preferred and LSCS is reserved for obstetric indications. Patient and family members are to be properly counselled. Team of doctors should be prepared to tackle any untoward event.

If diagnosed first time in labour or on operation theater (OT) table give intravenous atropine or isoprenaline infusion.

Plan safe delivery of diagnosed case of complete heart block in a tertiary care hospital where interventional cardiologists are available.



Conclusion

Every syncope should be taken seriously. ECG is a very cheap, reliable and easily available tool to diagnose such a grave condition as CHB. This condition could be completely asymptomatic during pregnancy and diagnosed only at the time of labor when patient comes in contact with the health facilities for the first time. Once diagnosed, it needs a multidisciplinary approach for management involving obstetrician, anesthesiologist and cardiologist. At last, the importance of putting your hand on the patient's pulse can never be undermined.



**DR PUNITHA RAJESH, MD(OG), FICOG., DGES(GERMANY)
SREEDEVI HOSPITAL & FERTILITY CENTRE, TRICHY**

RARE CASES OF UTERINE TORSION.

I would like to share about 2 cases of torsion of term gravid uterus, both of 180° torsion and identified during caesarean section and the incisions were made in the posterior uterine wall. Fortunately maternal and fetal outcomes are good in both the cases.

From the available literature:

Uterine torsion is an infrequently reported and potentially dangerous complication of pregnancy that occurs mainly in the third trimester with adverse maternal and neonatal consequences.

Torsion of the pregnant uterus is defined as rotation more than 45 degrees around the long axis of the uterus. Uterine torsion is observed in all age groups of the reproductive period, in all parity groups, and at all stages of pregnancy. Torsion from 60 degrees to 720 degrees has been described.

Clinical diagnosis is difficult since symptoms are either absent or non specific (cervical dystocia, painful uterine contractions, dynamic hypertonia...). It is not possible to clarify why uterine torsion occurs but is often associated with pathologies of the uterus such as uterine myomas or congenital deformities, abnormal fetal presentations, pelvic tumours or abnormal pelvis.

The most usual symptoms of uterine torsion are acute abdominal pain, fetal bradycardia, vaginal bleeding (APH) or failure of labor progress, vaginal bleeding, obstructed labour, shock, urinary and intestinal symptoms.

Eleven percent are asymptomatic. Preoperative diagnosis is challenging even with the use of ultrasound. The diagnosis is often made during cesarean sections.

The treatment in the earlier months of pregnancy is immediate laparotomy and detorsion of the uterus and, if practicable, adjunct surgery to eliminate the possible etiologic factors.

Laparotomy is used to establish the diagnosis and the management. Near term or during labor, cesarean section is carried out and elimination of the possible etiologic factors are carried out. Maternal prognosis is good after surgical treatment, however, perinatal mortality remains high. The fetal loss is reported as 12% and fortunately no maternal death is reported so far.



DR. N.THANTHONI D.N.B (OG)

^{1,2}OBSTETRICIAN AND GYNAECOLOGIST, SUNDARAM HOSPITAL, TRICHY

³SURGICAL GASTROENTEROLOGIST, SUNDARAM HOSPITAL, TRICHY

⁴OBSTETRICIAN AND GYNAECOLOGIST, MADHU HOSPITAL, PERAMBALUR

A CASE OF SPONTANEOUS SPLENIC RUPTURE IN TERM PREGNANCY CAUSING INTRAUTERINE FOETAL DEATH: A RARE ENTITY

THANTHONI N ¹, SHILPA VIVEK ², GURUPRASAD ³, LATHA RAJA ⁴

Abstract: Spontaneous splenic rupture in pregnancy is rare and occurs most commonly in third trimester or puerperium. It is usually misdiagnosed as abruptio placenta or uterine rupture. We are presenting a case of 27-year-old G2P1L1 previous normal delivery with 37 weeks of gestation, referred to our hospital with maternal tachycardia and abdominal pain, diagnosed as abruptio placenta with intrauterine death of foetus. Following delivery developed hemoperitoneum, diagnosed as splenic rupture and underwent emergency splenectomy.

Case Report

A 27-year-old G2P1L1 previous normal delivery with 37 weeks of gestation, no associated comorbidities with regular antenatal visits, presented to her obstetrician with complaints of acute abdominal pain, vomiting and giddiness. Her pulse rate was 120-130 per minute with BP of 90/50 mm Hg, intravenous fluids transfused. Foetal heart rate not audible with doppler, scan done revealed absent cardiac activity. She was referred to Sundaram hospital, a tertiary centre, as a case of abruptio placenta with intrauterine death of foetus.

On examination, patient was conscious, afebrile with no pallor. Her BP was 110/70 mm Hg and pulse rate was 130 per minute. Abdominal examination – uterus 36 weeks with cephalic presentation, not tense. On vaginal examination, cervix was partly effaced with 2 cm dilatation and intact membranes. Ultrasound done revealed absent cardiac activity with no evidence of retroplacental clot. Blood investigation done – Haemoglobin 10 gm %, elevated total leucocyte count – 24,000 /cumm with normal platelet count. Liver function test, renal function test and coagulation profile were normal. Cardiac evaluation done because of tachycardia, ECHO – normal.

IV antibiotics were given and labour was augmented with oxytocin. She delivered a dead born male baby,

weighing 3.5 kg with assisted vacuum. Placenta was removed manually under IV sedation because of retained placenta. Uterus was well contracted, bleeding within normal limits. BP – 100/70 mm Hg with tachycardia – 130 per minute.

Due to persistent tachycardia (pulse rate 120-130 per minute), repeat CBC was done after 6 hrs. Hb was 6 gm % (marked drop from 10 gm %) and elevated total leucocyte count – 22,000 /cumm. Patient had complaints of abdominal pain and left shoulder pain (Kehr’s sign). On examination, abdomen was mildly distended and tender. Uterus well contracted.

Abdominal ultrasound revealed free fluid in the abdominal cavity and splenic congestion with an area of infarct. CT angiogram revealed pseudoaneurysm in the spleen.

Splenic rupture suspected. Patient was taken up for emergency laparotomy. On opening the abdomen, 1.5 litres of hemoperitoneum present. On examining the spleen, a rupture of 3x2 cm identified on the inferior surface of spleen. Proceeded with splenectomy. 4 units of packed cells and 3 units of FFP transfused. Postoperative period was uneventful. Patient was discharged on the 5th postoperative day. Pneumococcal and influenza vaccination prophylaxis advised.

Splenic rupture might have occurred because of strain during vomiting. Active bleeding was not present immediately after rupture due to compression of the term uterus.

Discussion

Splenic rupture can be either traumatic or spontaneous. Spontaneous rupture occurs most commonly as result of pre-existing pathology of the spleen, such as Splenic aneurysm, Thalassemia or infectious etiology – Malaria, Typhoid or Infectious



mononucleosis [1,2,3].

Spontaneous rupture of a normal spleen without history of trauma is an extremely rare event. The hemodynamic changes that accompany pregnancy may predispose to spontaneous rupture through two mechanisms. First, the increased circulating blood volume causes congestion of spleen and reduced volume of peritoneal cavity due to expansion of gravid uterus may make the spleen more fragile and vulnerable to rupture [4]. Second, the circulating hormones such as estrogen and progesterone cause structural changes to the spleen that increase the risk of splenic rupture during pregnancy even after minimal trauma [5]. Minimal trauma such as coughing, sneezing, vomiting, straining for a bowel movement increase the intra-abdominal pressure, which is then transmitted to intra-abdominal organs.

The diagnosis of splenic rupture during pregnancy is difficult to make as it shares signs and symptoms with a number of other conditions, such as uterine rupture and placental abruption. The most frequent clinical symptom is left sided abdominal pain which commonly radiates to the left shoulder or chest [6]. This pain can become generalised with abdominal distension and rigidity. Signs of pallor and tachycardia are usually followed by hemorrhagic shock, DIC if timely intervention is not done. Abdominal ultrasound will help in diagnosis.

Conclusion

Splenic rupture in pregnancy is a rare complication with high maternal and foetal mortality. It should also be considered in the differential diagnosis of severe abdominal pain with tachycardia and hemoperitoneum in term pregnancy. Early diagnosis and surgical intervention will improve maternal and perinatal outcome.

References

1. Liu CF, Kung CT, Liu BM, et al. Splenic artery aneurysms encountered in the ED: 10 years' experience. *Am J Emerg Med* 2007;25: 430–6.
2. Adam I, Adam ES. Spontaneous splenic rupture in a pregnant Sudanese woman with *Falciparum malaria*: a case report. *East Mediterr Health J* 2007;13:735–6.
3. Boldorini R, Bozzola C, Gallarotti E, et al. Fatal splenic rupture in a pregnant woman with hemoglobin C/beta-thalassemia and myeloid metaplasia. *Arch Pathol Lab Med* 2006;130:1231–2.
4. Di Vella G, Arpaio A, Marzullo A, et al. Rupture of the spleen or splenic vessels (splenic emergency syndrome) in late pregnancy: a report of two autopsy cases. *Forensic Sci Int* 2008;176: e1–5.
5. Maymon R, Zimenman AL, Strauss S, Gayer G. Maternal spleen size throughout normal pregnancy. *Semin Ultrasound CT MR* 2007;28:64–6.
6. Bljajic D, Ivanisevic M, Djelmis J, Majerovic M, Starcevic V. Splenic rupture in pregnancy—traumatic or spontaneous event? *Eur J Obstet Gynecol Reprod Biol* 2004;115:113–4.



**DR. GAYATHRI. N. M.D., DNB, PGDMLE.
SHYAMALA NURSING HOME, TRICHY**

LAW IN MEDICAL PRACTICE – A FEW PRACTICAL TIPS

Of all the topics tutored in the medical college, the most neglected ones remain – Law pertaining to medical practice and the art of good doctor-patient communication. Even the art of communication, though not taught in a professional and scientific manner, the training period (CRRI) may provide the student with a base for at least a few practical tips and tricks. But apart from the medical subjects, these 2 happen to be the most vital in successful practice. The outcome of approximately 90% of the treatment in most specialties are good. Destiny is not decided by the doctor, it is designed by the Divine. But the current trend is, if the outcome is not within the expectation of the patient family, the doctor is expected to take the brunt of the blame. Increasing privatization and corporate setups further distance the doctor from the patients.

In this brief article, I would like to touch upon a few aspects which when put to practice can carry us a long way in our journey.

CONSENT:

In many circumstances, consents are written in just a few sentences even for major procedures.

“I, -----, give consent to undergo -----

(Procedure) under -----anesthesia.”

This type of consent will provide us with no protection in case of litigation. The law expects us to make the patient fully aware of the risks in any procedure before consenting to undergo the same.

When a patient comes to our OP and we advise them to have an injection, and they roll up their sleeves and stretch out their arm- this is implied consent. Similarly, when a surgical procedure is advised to the patient and they pack their things and come for admission for the said procedure, it is enough to imply that they are consenting to the procedure.

The important things that are to be mentioned in the consent include –

1. The complications of the said procedure in general and any specific risk factors of the patient, so as to make the patient at more risk for any complications, and the kind of management may be necessary, in the event of complications.
2. If this procedure is not done – what may happen to the patient (if the disease progressed).
3. What are the alternative treatment options available.



4. Who should be treated as proxy in case of emergency decision making during the procedure when patient is under anesthesia.
5. When the consent has all these points – it is said to be complete and will offer protection to the operating doctor and healthcare facility.

NEGLIGENCE:

Law does not want the doctor to do exceptional job to proclaim that there was no negligence. It demands only 3 things.

Is the doctor in question, adequately qualified to do the procedure.

Has the doctor managed the patient in any one way that is acceptable by an average doctor with the said qualifications. We all know that there are more than one type of treatment protocol for any said illness. As long as we choose a protocol from the accepted norm, we are not in any trouble. Problem arises when we go away from the regular protocols that are available in standard texts / guidelines.

Law also demands that the medical professional should not commit any act amounting to a blunder that an average doctor with the said qualification would not do under normal circumstances.

Important legal points that we need to know.

--When in emergency, importance only to save the life. Under such circumstances, no consent is required. If we document adequately and are able to sustain and prove that such and such procedure was done in good faith, to save the life of the

patient, even lack of consent is justifiable.

Be aware of your rights.

After a landmark judgement by the supreme court (Jacob Mathew) - No doctor can be arrested for any case pertaining to medical negligence. It pains to see incidence such as the one where a young gynecologist in Rajasthan allegedly committed suicide as she was arrested on account of a medical negligence case. Had she been aware of the legal rights – Viz a Viz—No arrest of any medical professional on account of case of medical negligence, such incidence can be prevented. Instead we could even bring the police down on their knees for contempt of court as the police have gone against the supreme court's judgement.

These are the bare minimum knowledge of law with reference to medical practice that a medical practitioner ought to know. In law, there is a famous Adage- "Ignorance of law is no excuse."

Thus, in this era where litigations are on the rise, it is time the NMC looks into this aspect and include at least the most basic features that we ought to know into the curriculum, so that we are more aware of our rights and responsibilities.



**DR.LOHA PUSHPANJALI.L.MD OG
UNDER THE GUIDANCE OF PROF.DR.PILLAI ARTHY.DGO,DNB.
DEPARTMENT OF OBSTETRICS AND GYNAECOLOGY,
SRINIVASAN MEDICAL COLLEGE AND HOSPITAL.**



LETHAL SKELETAL DYSPLASIA: RARE BUT CONCERNING.

The term “skeletal dysplasia” has been used to indicate a disorder of the skeleton. It comprises three entities—osteodysplasia, chondrodysplasia, and dysostosis.

Osteodysplasia refers to abnormalities of the bone leading to abnormal bone density and mineralization. Chondrodysplasias are abnormalities affecting cartilage associated with bone formation, leading to short stature. Dysostosis is focal anomaly of a bone or a group of bones that affects certain skeletal elements.

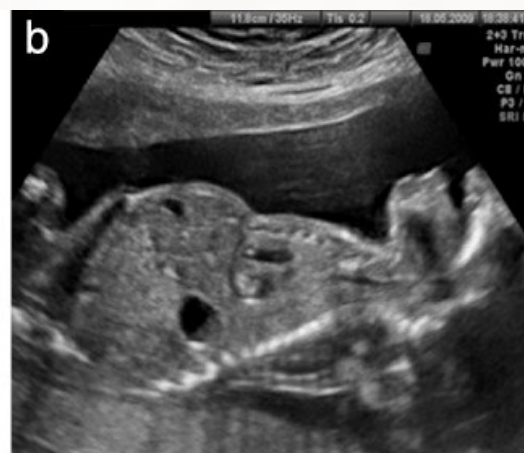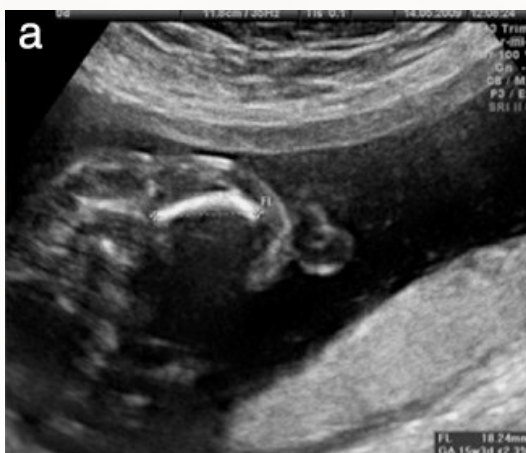For example, mutations in the transforming growth factor β gene may cause Camurati-Engelmann disease, a primary osteodysplasia, whereas mutations in the fibroblast growth factor (FGF) pathway can cause achondroplasia, thanatophoric dysplasia, or hypochondroplasia, which are considered primary chondrodysplasias. Spondylothoracic dysostosis refers to focal anomalies of the spine and ribs. An example of the aforementioned overlap is seen in recessive osteogenesis imperfecta caused by a 3-prolyl-hydroxylation complex that targets fibrillar collagen in both bone and cartilage, making it an osteochondrodysplasia. In this entity the bones are fragile, and the growth plate is also affected.

Entities with similar clinical and radiographic characteristics were eventually grouped into bone dysplasia families, predicting possible molecular gene abnormalities. This classification underwent numerous revisions. The latest was published in 2015 and includes 436

entities and 364 known genes. The current classification is based on a number of identifiers, including the following: a single gene or group of genes, such as the FGFR3 chondrodysplasia group or the collagen type II group; a particular phenotype (dysplasias with multiple joint dislocations or the slender bone dysplasia group); or a certain radiologic finding (including the metaphyseal and diaphyseal dysplasias or the chondrodysplasia punctata group). This classification yielded 42 groups in which all of the skeletal dysplasias known to date are characterized.

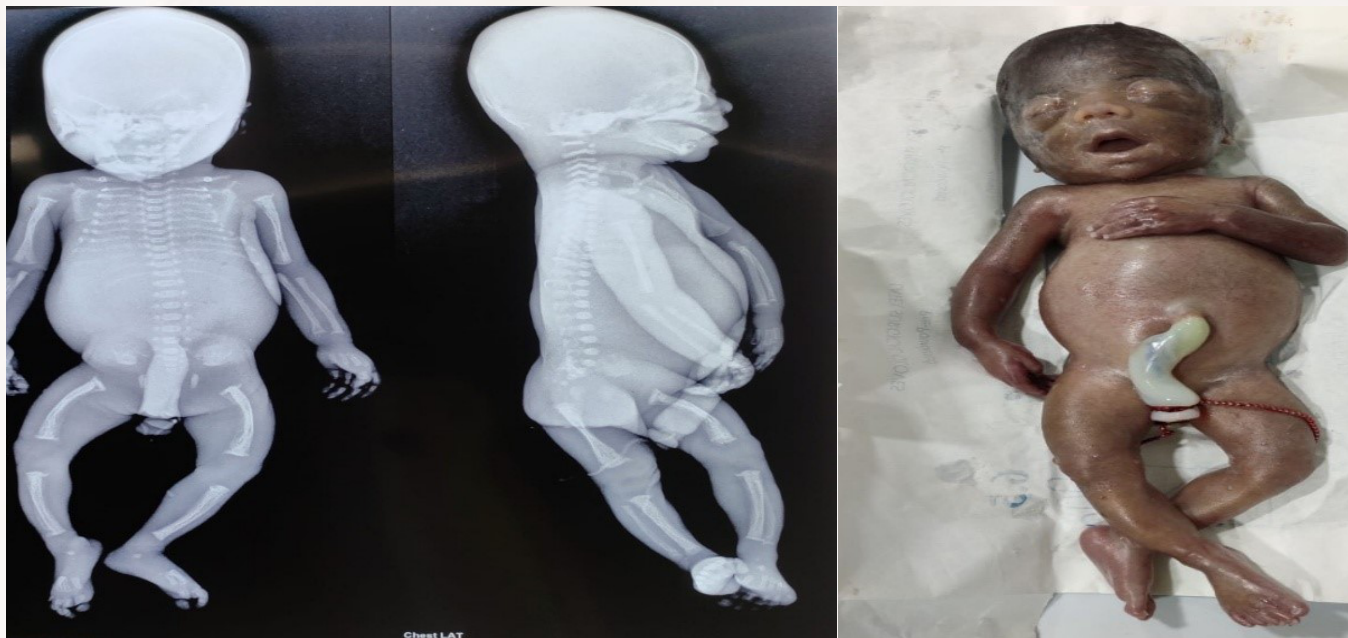Obstetric ultrasonography is routinely used to screen for fetal anomalies. Thanatophoric dysplasia (TD) is one of the common though rare lethal skeletal dysplasia, detected during routine ultrasound scan. TD is caused by a mutation in FGFR3 gene. Characteristic features include shortening of limbs, macrocephaly and platyspondyly.

We at Department of Obstetrics and Gynaecology, Srinivasan Medical College and Hospital have encountered one such case, A 23 year old G3A2, who was on regular antenatal checkup with no comorbidities. She has had spontaneous abortions and following which she had spontaneous conception. She has had normal NT scan report. Patient reviewed



us with Anamoly scan report showing Lethal skeletal dysplasia. The ultrasound scan at 24 weeks showed a biparietal diameter of 25weeks and a femur length of 14 weeks. The thoracic cage was narrowed with hypoplastic lungs and short ribs, and the heart was centrally occupying the chest. The femur, tibia, fibula, humerus, ulna, and radius were shortened (micromelia). Based on these findings, thanatophoric dysplasia type 1 diagnosis was made.

Ultrasound images of a case of thanatophoric dysplasia Type 1 (Case 1) at 20 weeks' gestation showing short, curved femur (a) and narrow fetal thorax (b).



Thanatophoric dysplasia is a short limb skeletal dysplasia. It is a congenital and sporadic condition. Thanatophoric dysplasia was previously described as thanatophoric dwarfism, but currently, this term is no longer used. Thanatophoros is a Greek word meaning "death bearing". It is caused by an autosomal dominant mutation in FGFR 3 gene. Incidence of thanatophoric dysplasia (TD) is 1:20,000 to 1:50,000. Both sexes are equally affected, with no racial or ethnic predisposition.

There are two subtypes. Type 1 accounts for about 80% of cases and type 2 accounts for 20%. The subtypes can be differentiated by the morphologic features of the femur and the shape of the skull. Type 1 is characterized by curved or bowed femurs, and type 2 is characterized by straight femurs and a cloverleaf skull.

The current case had TD type 1. Features common to both subtypes include micromelia, short ribs, narrow thorax, brachydactyly, redundant skin folds along the limbs, distinctive facial feature, and relative macrocephaly. All these features were present in the index case. Although formal diagnostic criteria for thanatophoric dysplasia have not been established, diagnosis is based on clinical characteristics and/or radiologic features and/or molecular genetic testing

A. Infantogram showing bowing of left ulna and both femora and tibia, short ribs, and platyspondyly.

B. External features showing dolicocephalic head, depressed nasal bridge, short and bowed limbs,

narrow thorax and protuberant abdomen.

Clinical course usually involves most fetuses dying in utero or some few hours after birth, with respiratory insufficiency usually being the cause of death. This may be due to the narrow chest and hypoplastic lungs or brain stem compression or both.

Although thanatophoric dysplasia is rare, this case report emphasizes the need for insight regarding the problem and the importance of early prenatal diagnosis to aid in alternative options of termination of pregnancy and to avoid potential pregnancy complications.



DR. PRIYADHARSHINI MOHANASUNDARAM
MBBS, MD, MRCOG (UK), MICOG, FELL REPRODUCTIVE MEDICINE
ASSISTED CONCEPTION (BFS CERTIFIED)
MAZHALAI FERTILITY CENTRE, SUDHARSANA HOSPITAL, TRICHY

FERTILITY PRESERVATION

Fertility preservation (FP) is an emerging field in medicine that enables men, women, and children to maintain reproductive health when it is threatened by gonadotoxic treatment. Patients affected by other nononcologic malignancies that can impair spermatogenesis and oogenesis can also benefit from FP treatments. Age-related infertility can also be overcome by cryopreserving gametes or embryos. FP treatments must be addressed through a multidisciplinary approach that involves gynecologists, urologists, oncologists, pediatricians, and professionals in the field of medically assisted reproduction to work in coordination to provide patients with counseling and comprehensive information about fertility issues.

Introduction:

Fertility preservation provides the opportunity to maintain reproductive health to all those patients who either have to receive gonadotoxic treatment for medical reasons or want to preserve their gametes to postpone childbearing (age-related). The majority of patients who can benefit from FP techniques are cancer patients. Chemo- and radiotherapy given in cancer therapies have detrimental consequences on male and female gonads that may lead to infertility. Other disorders, such as autoimmune diseases (e.g., lupus) and myelodysplastic syndromes, require medical treatment that can also impair reproductive cells and tissues. The main target of these therapies is the cellular cycle, and the interruption or arrest of the cellular cycle causes severe defects in the DNA replication and transcription mechanisms that could lead to cell death. Nevertheless, the undesirable effects of those therapies depend on various factors, such as the intrinsic characteristics of the patients (age, general health status, genetic disposition, sensitivity of

tissues, cell-repair mechanisms), therapy (total dose and irradiated field in radiotherapy, type of chemotherapy agent), and tumour biology.

Men and women are affected by gonadotoxic therapies in different ways. The reproductive damage caused in the male is mainly focused on sperm quality and germinal epithelium. Since spermatogenesis is maintained throughout life from puberty, damage caused by gonadotoxic therapies can usually be reversed after treatment. There is evidence of significant recovery of gonadal function in the first 10 years after treatment. In women, radio- and chemotherapy can affect ovaries and uterus, threatening ovarian reserve and uterine vascularization.

Apart from oncological patients, FP is also indicated in other circumstances where germ cell degeneration is observed. Women affected by premature ovarian failure (POF) may also benefit from FP. In men, Klinefelter syndrome affects 1 of 600 male newborns. Germ cell degeneration in affected patients starts in utero and progresses through infancy and adolescence. Sperm cryopreservation in adolescent patients prior to achievement of azoospermia (90% of cases) should be performed as a strategy for FP.

Furthermore, in recent decades, a social trend toward delaying childbearing has been observed in women of reproductive age. This delay is due to different factors related to lifestyle (such as development of a professional career or absence of the right partner). As a consequence, these women may be affected by age-related infertility when they decide to conceive, and FP techniques may also be indicated in this population. Sperm cryopreservation is a well-established technique that enables men who wish to preserve their fertility for social reasons to maintain their gametes



stored in liquid nitrogen. Sperm cryopreservation is considered a standard procedure prior to vasectomy. Men exposed to toxins or those whose work in extreme conditions can adversely affect spermatogenesis, are also candidates for FP.

Male Fertility Preservation

Cancer Patients

Today, two-thirds of patients survive at least 5 years after being diagnosed with cancer. Advances in oncological research and improvement in cancer screening and treatment have increased survival rates and improved the quality of patients' lives.

Effects of Cancer on Male Reproductive Health

The disruption of the hypothalamic-pituitary-gonadal axis induces a breakdown of the spermatogenesis process. In testicular cancer, the malignancy also triggers immunologic and cytotoxic injuries on testicular germinal epithelium that affect testicular environment. Taking into account that neoplastic processes can be considered a systemic illness, the affected individuals can develop some associated somatic disorders, such as fever and malnutrition, and some psychological disorders, such as anxiety and/or depression, that will certainly have a negative impact on reproductive health.

Effects of Cancer Treatment on Male Reproductive Health

In male cancer patients, surgery, radiotherapy, and chemotherapy can be followed by transient or permanent infertility by affecting ejaculatory or erectile function, or by impairing spermatogenesis.

Surgery Bilateral orchiectomy in testicular cancer results in a lack of production of both testosterone and sperm, resulting in permanent infertility. Unilateral orchiectomy reduces the sperm concentration in semen samples. Reduced spermatogenesis is reversible within the first year after surgery in survivors who recover almost normal follicle-stimulating hormone (FSH) levels. Retroperitoneal lymph node dissection, performed mainly in testicular carcinoma, renal cell carcinoma, and upper urinary tract urothelial carcinoma, causes serious disruption of ejaculation. Prostate cancer patients who have to undergo radical prostatectomy suffer from erectile dysfunction that

will impair fertility. Retrograde ejaculation and loss of semen quality have also been described after prostatectomy. Erectile dysfunction can also be produced by surgery for cancer of the rectum.

Radiotherapy has severe side effects upon male fertility. Irradiation in the G2 phase of the cell cycle induces chromatid aberrations. The chromosomal damage can be individually measured by analysing the dose/response to radiotherapy of peripheral blood cells.

Detrimental effects of radiotherapy depend on dose and irradiation field. A 2-Gy dose of irradiation leads to azoospermia. This situation can be overcome in some cases in approximately 30 months. Total body irradiation (TBI) performed in haematological cancers prior to bone marrow transplantation or hematopoietic stem cell transplantation and abdominal or pelvic radiotherapy put patients at high risk of developing permanent infertility. Less than 20% of patients recover gonadal function after TBI. Furthermore, spermatogenesis can be disrupted since radiotherapy combined with chemotherapy increases FSH levels in approximately 70% of patients.

The vast majority of chemotherapeutic agents are gonadotoxic. Alkylating agents seem to present the greater risk of causing infertility, largely due to azoospermia. Other chemotherapeutic agents, such as platinum compounds, can also cause azoospermia in 50% of patients. Besides the decrease in sperm count produced by these oncologic treatments, DNA of spermatozoa can also be impaired. It has been demonstrated that DNA integrity can be recovered after treatment.

Strategies for Male Fertility Preservation

Sperm Cryopreservation

The sperm cryopreservation technique that seems to be more efficient is the rapid freezing protocol. Survival rates after sperm cryopreservation allow pregnancy rates comparable to the ones obtained with the use of fresh samples.

Testicular Tissue Cryopreservation

In rare cases where FP needs to be carried out in obstructive azoospermia adult men, testicular sperm aspiration or testicular sperm extraction (biopsy) is performed.

No FP options exist for prepubertal boys. In 1994, Brinster and Zimmerman reported the successful transplantation of male germ cells in a rodent model. They proved that spermatogenesis could be induced from the transplanted stem cells in a sterile recipient mouse. This method of spermatogonial stem cell transplantation into the testis shows a potential strategy of fertility preservation in prepubertal boys undergoing a cytotoxic treatment.

Female Fertility Preservation

Cancer Patients

Breast, cervical, and colorectal cancers are the leading cancers in women worldwide. Approximately 4% of women with cancer will be younger than 35 years of age at the time of diagnosis, and breast cancer is the cancer with the highest incidence in this population. Some of these patients may have disease identified at an early stage and can potentially be cured, with fertility preservation being an important issue at the time of disease diagnosis. Furthermore, the continuous delay of childbearing observed in developed countries will result in an increased proportion of women diagnosed with cancer before their first pregnancy.

Effects of Cancer on Female Reproductive Health

Cancer causes an increased metabolic state and hypothalamic dysfunction that may lead to infertility. It has been reported that oocyte quality is apparently affected by the malignancy and that female carriers of BRCA1 mutation may be low responders to ovarian stimulation. Somatic disorders, such as anxiety and depression associated with the oncologic process, also have a negative impact on reproductive health.

Effects of Cancer Therapies on Female Reproductive Health

Cancer therapies are known to affect reproductive health, although the effects may be unpredictable since the exact apoptotic pathways involved are still unknown.

Ovarian damage caused by radiation depends on the patient's age, the dose, and the field of irradiation. Radiation therapy to the pelvis can have a direct negative impact on ovarian function and on the uterus by altering vascularization and by reducing growth if

treatment is received during childhood.

Doses of 4–6 Gy can produce a loss of 50% of the follicular population, whereas total body irradiation represents a high risk of ovarian failure in treated patients (55%–80%). It is also known that younger women (<40 years) are less affected by irradiation damage. Nonpelvic radiation (e.g., cerebral irradiation) can also impair fertility by affecting the hypothalamic-pituitary axis, causing a malfunction in oogenesis.

Chemotherapeutic agents affect ovarian function by several mechanisms, such as follicular depletion (burn-out mechanism), vascular damage, and cortical fibrosis. The patient's age at treatment and the chemotherapy regimen (type and dose) both influence the risk of premature ovarian failure. Older women have a higher risk of presenting permanent infertility. It has been demonstrated that women younger than 40 years old exposed to chemotherapeutic agents have a 61% risk of developing amenorrhea, and this figure increases to 95% in women older than 40 years. Alkylating drugs such as cyclophosphamide are the most gonadotoxic agents since they are not cell cycle-specific, and they also affect other cells in the ovary.

Strategies for Fertility Preservation in Women

Oocyte Cryopreservation

With the methodological improvements achieved with vitrification, clinical pregnancy rates and live birth rates with frozen-thawed oocytes are comparable to those obtained with fresh cycles. Although children born from vitrified oocytes do not present higher rates of congenital anomalies than those born from fresh oocytes, long-term safety is still to be proved. As a consequence, oocyte cryopreservation has become an alternative to embryo freezing in IVF programs and constitutes a real option for fertility preservation.

Oocyte cryopreservation constitutes a strategy of fertility preservation for patients who can postpone oncologic treatment and when controlled ovarian stimulation is not contraindicated. It is a valid option for postpubertal women without a male partner or those who do not accept donor sperm and have moral objections to embryo cryopreservation. Nowadays, age-related fertility preservation is performed mainly by oocyte vitrification. The whole process of oocyte cryopreservation (ovarian stimulation and oocyte



retrieval) takes a minimum of 2–3 weeks, depending on patient's menstrual cycle. The use of gonadotropin-releasing hormone (GnRH) antagonists allows a random start of stimulation and provokes luteolysis within 2–4 days, with subsequent follicular development. This is a useful strategy when there are time constraints and the patient is not in the early follicular phase. The exposure to high levels of estradiol may be contraindicated in patients with hormone-dependent tumors. However, there is controversy about this issue, since some authors believe that there is no real risk in having a short-term increase in hormonal levels. Nonetheless, ovarian stimulation protocols with aromatase inhibitors have been described in order to avoid excessive high estradiol levels, and no increase of recurrence rate of breast cancer has been observed with this treatment.

Embryo Cryopreservation

To date, embryo cryopreservation is the most standardized procedure of fertility preservation. High survival rates and cumulative pregnancy rates of 60% support the fact that it constitutes a clinically well-established technique. The need of a male partner or sperm donor for embryo cryopreservation is a requirement that not always can be fulfilled.

Ovarian Tissue Cryopreservation

Ovarian tissue cryopreservation may be still considered an experimental technique. To date, approximately 20 children have been born worldwide after ovarian tissue cryopreservation. Ovarian tissue is obtained by laparoscopy, and it is frozen or vitrified in thin slides. Primordial follicles are located in ovarian cortex, and they are relatively resistant to cryoinjury. Nonetheless, after ovarian tissue thawing and grafting, a massive loss of follicles is observed during the ischemic period until revascularization is established. Revascularization of tissue graft results in some living follicles that grow and develop mature oocytes. Because of the lack of a worldwide registry, the effectiveness of the technique is unknown, but this constitutes the only option for prepubertal girls and for women who cannot delay cancer treatment or cannot undergo controlled ovarian stimulation.

One of the concerns regarding thawed ovarian tissue transplantation is the risk of reseeding malignant cells. Transplantation of thawed ovarian tissue is contraindicated in patients with leukemia because of

the high risk of relapse. Some authors have reported that there seems to be no risk of reintroducing malignant cells for women with Hodgkin's disease or at early stages of breast cancer. Transplantation of ovarian cortical fragments can be done either orthotopically (in the peritoneal cavity) or heterotopically (forearm or anterior abdominal wall, probably associated with poorer oocyte quality due to inadequate environment). Neoangiogenesis after ovarian tissue transplantation is still the limiting factor as it takes 5 days and leads to 60% loss of primordial follicles. Pregnancies reported to date have been both spontaneous and after IVF. Transplantation of the whole ovary with its vascular pedicle still remains an experimental procedure in humans.

Hormonal Protection by Ovarian Activity Suppression

Ovarian protection from gonadotoxic treatment with GnRH agonists is still controversial. The idea of maintaining the ovarian metabolism quiescent to avoid any damage caused by oncologic treatment is still to be confirmed, and there are doubts about whether GnRH agonist administration has a potential beneficial effect on ovarian tissue because of the lack of FSH receptors on primordial follicles.

Ovarian Transposition

The surgical procedure of ovarian transposition intends to move ovaries outside the irradiation field. Laparoscopic ovarian transposition consists of releasing the ovary from its pelvic attachments and placing it behind the uterus or in the paracolic gutter. This strategy is especially useful in patients with cervical cancer who require only radiotherapy for cancer treatment.

In Vitro Maturation of Human Oocytes

Retrieval of immature oocytes followed by oocyte in vitro maturation (IVM) is one of the strategies in cases in which ovarian stimulation is not possible. Oocyte retrieval is usually performed prior to ovulation, but immature oocytes can also be recovered during both the follicular and luteal phases. Oocyte cryopreservation after IVM can be performed using vitrification or slow freezing techniques. Vitrification of IVM oocytes has resulted in a live-birth rate of 20%; nonetheless, survival and fertilization rates of IVM oocytes are lower than those of in vivo-matured ones.

Vitrification of in vitro matured oocytes combined with ovarian tissue cryopreservation represents a strategy for fertility preservation when ovarian stimulation is contraindicated.

Follicular Culture

In vitro follicular culture has been proposed as an alternative to ovarian tissue transplantation to avoid the risk of reintroducing malignant cells. The aim of this technique is to develop an in vitro system that allows the growth of primordial and primary follicles to antral stages in order to obtain mature oocytes. Given the complexity of follicle genesis in vivo, much research in culture conditions is still necessary in order to achieve results that can be applied in clinical practice.

Ethical Aspects of Fertility Preservation

The emerging trend of FP in clinical practice is bringing new treatment options that may imply ethical dilemmas. Fertility preservation in patients experiencing malignancies and fertility preservation in women who are free from disease and wish to avoid age-related fertility loss are sometimes controversial because of the uncertainty of using the cryopreserved material in the future and the doubtful benefit to the patients.

As a result of more effective treatments, the long-term survival rate of childhood and young adult cancer patients has raised over the past few decades. Almost 80% of children diagnosed with malignancy will recover from the illness. Infertility is an issue that is important to cancer patients and their families and that must be addressed. Realistic information about the new advances in fertility preservation and chances for the future should be given in order to ensure appropriate counselling and treatment.

FP in girls during childhood due to non-oncological conditions (repeated ovarian surgery, genetic disorders) may be controversial because of the uncertainty of predicting which patients are at risk for POF; which are the fertility preservation methods available for girls; and the feasibility, safety, and efficacy of these methods.

Conclusion

Fertility preservation is a multidisciplinary field that requires the collaboration and coordination of professionals from different specialties. Oocyte, sperm, embryo, and ovarian tissue cryopreservation

offers patients real options of preserving fertility. It is important that individuals under threat of fertility loss are offered appropriate fertility preservation options.

Ensures Embryonic Development

Blasto Q300®

Coenzyme Q10 300mg & Melatonin 3mg Tablets



Erectile dysfunction Male Infertility

Blasto Q Forte

Yohimbe berk extract 20mg, Tribulus terrestris 100mg, Coenzyme Q10 50mg, Mucuna pruriens 50mg, Asparagus sarmentosus 50mg, Ginkgo biloba 20mg, Ashwagandha withania somnifera 150mg, Fenugreek 5mg, Hygrophila spinosa 90mg, Myristica fragrans 10mg, L-Arginine 10mg, Piperine 5mg, Resveratrol 10mg



Oocyte Quality and Embryo Counts

QWIN-ANDRO 75

Soft Gelatin Capsules

Dehydroepiandrosterone 75mg, Ubiquinol Acetate 100mg, Melatonin 3mg, L-Methylfolate calcium 500mcg, Vitamin D3 10mcg **Soft Gelatin Capsules**

Rx

In PCOS Management

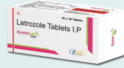Gynova Plus

N-Acetyl L Cysteine 300mg, Myo Inositol 550mg, D-Chiro Inositol 13.8mg, Astaxanthin 8mg, L-Glutathione 50mg, Ubiquinol 30mg, D-Biotin 30mcg, Vitamins and Minerals Tablets

Super Ovulation

GynoLET

Letrozole 2.5mg Tablets



Queewin-50

Coenzyme Q10 50mg, Clomifene Citrate 50mg Tablets

It is an effective and safe option and can be considered before gonadotropin therapy for laparoscopic ovarian drilling



A conclusive pro biotic to aid **Genital Health...**



Sporcalm LL

Lactobacillus acidophilus 2 billion CFU + Lactobacillus rhamnosus 2 billion CFU + Lactobacillus reuteri 2 billion CFU + Lactobacillus plantarum 1 billion CFU + Lactobacillus casei 1 billion CFU + Lactobacillus fermentum 1 billion CFU + Bifidobacterium Bifidum 1 billion CFU + Fructo Oligosaccharide 100mg + Lactoferrin 50mg **Veg Capsules**

Bacterial Vaginosis

Human Papilloma Virus (HPV)

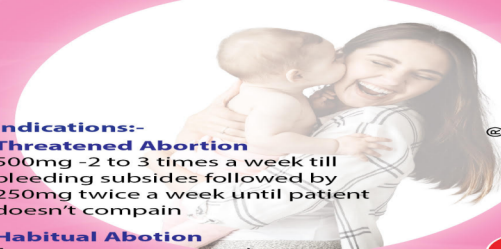Indications:

Senile vaginitis | UTIs

Genito-urinary Syndrome of Menopause (GSM)

Maintaining the healthy community of microbes for Good health...

The Ultimate Progestogen



Indications:-

Threatened Abortion

500mg -2 to 3 times a week till bleeding subsides followed by 250mg twice a week until patient doesn't complain

Habitual Abortion

As soon as pregnancy is confirmed 250mg or 500mg weekly for 1 month

Painless technology

Brightens the hope of motherhood...

CORPOGEST 250 500
17- α Hydroxy Progesterone Caproate Injection

When luteal Phase Physiology is Disrupted in IVF Cycles...

CORPOGEST GEL

Progesterone (Natural Micronised) Gel 8.0%w/w

In:-

Assisted Reproductive Techniques like:
In vitro Fertilisation/ Intracytoplasmic Sperm Injection
Embryo Transfer | Gestational Surrogacy
Gamete / Zygote Intrafallopian Transfer
Tubal Embryo Transfer | Oocytes and Embryo Donation

Corpegest 8% gel is administered Vaginally at a Dose of 90mg Twice Daily in Women with Partial or Complete Ovarian Failure who require Progesterone Replacement

Corpegest 8% gel is Administered Vaginally at a Dose of 90mg Once Daily in Women Who Require Progesterone Supplementation

A Natural Luteal Support for Favourable IVF Outcomes...





DR REVATHY M C CHANDRASEKARAN,
 MBBS,MS(OG), ICOG FETAL MEDICINE SPECIALIST (GOLD MEDALIST)
DR MALATHI G PRASAD,
 MD, FRCOG(UK) DIPLOMA IN FETAL MEDICINE(FMF BARCELONA)
TRICHY FETAL MEDICINE CENTRE, TRICHY.



SKELETAL DYSPLASIA - A GENETIC CASE REPORT

Abstract: This is a genetic case report of skeletal dysplasia.

Keywords: genetic case, skeletal dysplasia, thanatophoric dysplasia, silverman handmaker, dyssegmental dysplasia.

Introduction: Skeletal dysplasia are a group of skeletal abnormalities which can be either lethal or non-lethal. Due to the advancement in diagnostic modalities, standardised ultrasonographic evaluation protocol, enhanced objective diagnosis by nomograms, the diagnosis of skeletal dysplasia's in prenatal period has sharply increased. Owing to its high lethality, morbidity and high recurrence rate, a case of skeletal dysplasia has to be systematically evaluated for its genetic component to prognosticate present and future pregnancy.

Case report: 23 year old Mrs.A, G2P1L0NND1, consanguineously married to her 31 year old husband Mr. B, with no positive family, past and personal history. Both the partners were healthy with normal physique and BMI standardised for the local population. Her first pregnancy on 2018 was a term vaginal delivery with no adverse antenatal events except for polyhydramnios detected at 37 weeks USG. Soon after the birth, baby was noticed to have ambiguous genitalia, low ano-rectal malformation, short limbs and narrow thorax suggesting lethal skeletal dysplasia, baby was admitted in NICU due to respiratory distress and died at 3 days of age. No further evaluation of the baby was carried out. Patient came to our centre in 2019 in her second pregnancy for targeted anomaly scan at 18 weeks, where the fetus was evaluated thoroughly and found to have short long bones ($< 2SD$) and narrow thorax (cardio-thoracic ratio- 0.6), femur-foot ratio - 0.6 suggestive of lethal skeletal dysplasia. Invasive testing by amniocentesis for multigene-panel for skeletal dysplasia was carried

out. Pathogenic FGFR3 mutation in heterozygous state, autosomal dominant inheritance pattern, was found concluding the fetus to be affected by thanatophoric dysplasia type 1. The parents went ahead and terminated the pregnancy. Postnatal autopsy confirmed the diagnosis. Parental carrier testing was done on 2021 in which Mr. B was found to be not a carrier of the affected gene. Mrs. A was found to be a carrier of 3 genetic mutations but not matching the phenotype of the affected index child. The couple came in 2022 with their third pregnancy at 12 weeks which was a spontaneous conception di-chorionic di-amniotic twin gestation. Prenatal testing by chorionic villus sampling was carried out for mutation matching, which showed both the fetus are affected by pathogenic FGFR3 and ZNF335 mutation which are thanatophoric dysplasia type 1 and microcephaly 10 respectively. Upon finding recurrent FGFR3 mutation in 2 consecutive pregnancy with the partners testing to be non-carrier of Pronounced mutation, a provisional diagnosis of germ cell mutation was made and extensive counselling was given to the couple regarding PGT and option of Donor gametes and IVF. Our team wanted to Re-analyse the raw data of both the partners and we found that both Mrs.A and Mr.B to be carrier HSPG2 mutation - Dyssegmental dysplasia, silverman handmaker an autosomal recessive disease in heterozygous state whose pathogenicity is variant of unknown significance. Now we Re-analysed raw data of DCDA fetus which also showed HSPG2 mutation - Dyssegmental dysplasia, silverman handmaker an autosomal recessive disease but in heterozygous state(carrier status). There was a genetic dilemma regarding the significance of HSPG2 mutation in causing recurrent skeletal dysplasia in this case. The case was concluded with a detailed counselling regarding the above findings that in future pregnancies if the prenatal scans shows features of skeletal dysplasia, HSPG2 gene variants should be



confirmed in the fetus by invasive testing to confirm the correlation with the phenotype. The clinical phenotype and radiological phenotype should also be delineated by postnatal examination and radiological survey.

Discussion: Ultrasound evaluation is found to be the most sensitive tool for detection of Fetal skeletal abnormalities. Diagnosis of skeletal abnormality by USG will be influenced by maternal habitus, fetal position, amniotic fluid volume and gestational age. The pre-requisite for a precise and early diagnosis of skeletal dysplasia is thorough mid-trimester USG with systematic evaluation of fetal skeletal system starting from skull till hands and feet. An anomaly in fetal skeletal system if found, detailed expert scan with molecular testing of the fetus according to the phenotype including extensive counselling and consultation with paediatrician/ surgeon should be arranged. If a diagnosis of Lethal skeletal dysplasia be made, option of termination of pregnancy to be given to the expectant couple. If the couple decide to continue the pregnancy, close monitoring and neonatology and paediatric surgeon consultation to be arranged.

Conclusion: Although skeletal anomalies are difficult to diagnose antenatally, a detailed scan of a complete fetal anatomy between 20 and 32 gestational weeks with special attention given to the entire skeleton, gives certain assurance of excluding majority of major skeletal dysplasias or enables their diagnosis and further adequate plan for pregnancy management. Evaluation of parents and family members with detailed family history should be the primary step in evaluation followed by detailed ultrasonography to assess phenotype and associated anomalies to look for syndromic presentation. Genetic counselling and Molecular testing for single gene disorder to prognosticate present and future pregnancies is a vital step in evaluation of skeletal dysplasia.

Ethical approval about publication:

Ethical approval not required. The patient's permission was obtained.

Disclosure of funding: None

Conflict of Interest:

No potential conflict of interest relevant to this article

was reported.

Authors contribution:

Data gathering: Malathi G prasad, Trichy fetal medicine centre, trichy.

Writing manuscript: Revathy M C, Trichy fetal medicine centre, trichy.

Editing and approval of final draft: Malathi G prasad, Revathy M C

Approval of final draft: Malathi G prasad, Revathy M C

Reference:

- Schild R. L., Hunt G. H., Moore J., Davies H., Horwell D. H. Antenatal sonographic diagnosis of thanatophoric dysplasia: a report of three cases and a review of the literature with special emphasis on the differential diagnosis. *Ultrasound in Obstetrics and Gynecology: The Official Journal of the International Society of Ultrasound in Obstetrics and Gynecology*. 1996;8(1):62–67. doi: 10.1046/j.1469-0705.1996.08010062.x. [PubMed] [CrossRef] [Google Scholar]
- French T., Savarirayan R. In: *Thanatophoric Dysplasia*. Adam M. P., Ardinger H. H., Pagon R. A., editors. Seattle (WA): University of Washington, Seattle; 2004. [Google Scholar]
- Tirumalasetti N. Case report of Thanatophoric dysplasia: a lethal skeletal dysplasia. *Journal of Dr. NTR University of Health Sciences*. 2013;2(4):275–277. doi: 10.4103/2277-8632.122168. [CrossRef] [Google Scholar]
- Garjian K. V., Pretorius D. H., Budorick N. E., Cantrell C. J., Johnson D. D., Nelson T. R. Fetal skeletal dysplasia: three-dimensional US--initial experience. *Radiology*. 2000; 214(3): 717–723. doi: 10.1148/radiology.214.3.r00mr23717. [PubMed] [CrossRef] [Google Scholar]
- Sharma M., Jyoti R. J. Thanatophoric dysplasia: a case report. *Journal of Clinical and Diagnostic Research: JCDR*. 2015; 9(11): QD01–QD03. doi: 10.7860/JCDR/2015/13201.6702. [PMC free article] [PubMed] [CrossRef] [Google Scholar]
- Tonni G., Azzoni D., Ventura A., Ferrari B., Felice C. D., Baldi M. Thanatophoric dysplasia type I associated with increased nuchal translucency in the first trimester: early prenatal diagnosis using combined ultrasonography and molecular biology. *Fetal and Pediatric Pathology*. 2010;29(5):314–322. doi: 10.3109/15513811003796938. [PubMed] [CrossRef] [Google Scholar]
- Jahan U., Sharma A., Gupta N., Gupta S., Usmani F., Rajput A. Thanatophoric dysplasia: a case report. *International Journal of Reproduction, Contraception, Obstetrics and Gynecology*. 2019;8(2):758–761. doi: 10.18203/2320-1770.ijrcog20190319. [CrossRef] [Google Scholar]



**DR. THAMIZHSELVI NAVEEN, MD(OG), DNB(OG), FRM
SPRINGDALE WOMEN'S CLINIC, TRICHY**

ARTIFICIAL INTELLIGENCE (AI) IN INFERTILITY

INTRODUCTION:

Assisted Reproduction Technology (ART) treatments have undergone many modifications and expansions since the successful birth of Louise Browne in 1978. Despite these advancements, only one third of ART cycles result in a live birth till date. It has been estimated that only 5% of the aspirated oocytes have the competence to develop into a fetus.

In recent years, the development and implementation of artificial intelligence (AI) technology have shown the potential to address inefficiencies in various steps of ART, including the standardization of some IVF laboratory processes and particularly in sperm and embryo selection. Indeed, AI is also being proposed for clinical applications including diagnostics and precise treatment paths in combination with digital devices remotely collecting real-time data to be analysed.

This implies that there is always room for improvements and there is possibility for enhancement in the crucial steps of ART resulting in an increase in the number of successful live births per ART cycle in the years to come. Improving the ability to select a sperm for ICSI or an embryo with the highest implantation potential could increase live birth rates. As video and image analysis constitute a major part of ART, AI are well suited for this purpose in ART cycles. AI has the advantage of objectivity, reproducibility and reduction in biases due to subjective analysis which can theoretically improve the outcome if properly performed.

DIFFICULT SCENARIOS IN ART:

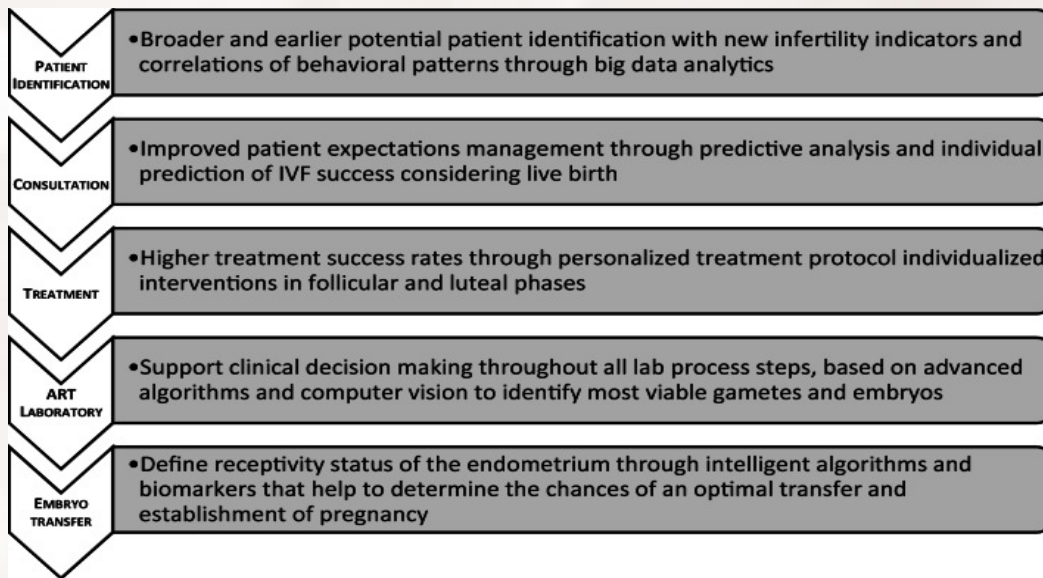
We, as clinicians face day to day challenges and difficult decision-making scenarios such as like which fertilization method to use, which spermatozoon to

select for ICSI or which embryo to transfer to the uterus in our patients frequently. While sperm morphology has no definite impact on the outcome of ART, sperm motility and concentration are usually assessed to decide which method of fertilization to be used, either IVF or ICSI. WHO guidelines for standard semen analysis is usually followed and it is a time-consuming method. This method also has the disadvantage of limited reproducibility and high inter- personnel variation. Numerous computer-aided sperm analyses (CASA) systems are available, but their reliability is still debatable. The selection process of sperm for ICSI is highly prone for subjective bias and is completely based on the qualitative evaluation of the operator and not on the objective sperm characteristics. One of the major challenges in embryo selection is the intra - and inter - operator variability that exists in the subjective evaluation of morphology and morphokinetics of the embryos. Although time-lapse helps in monitoring the embryos continuously, there is no evidence that this technology improves the live birth rates.

WHY AI?

In recent years, AI has proven consistently to be a valuable tool in medicine by analyzing large amounts of data. As high-quality cameras and data capturing systems are increasingly becoming a highly integrated part of the fertility centers, a vast amount of stored data like patient data, sperm videos, ICSI videos, embryo time-lapse videos are becoming available in recent years. These data can be easily incorporated into, analyzed by and utilized by AI in a hassle-free manner.

The image depicts how AI can be incorporated into an ART clinic setup to be utilized on a day to day basis and to collect data to be incorporated for further research in developing new AI algorithms:

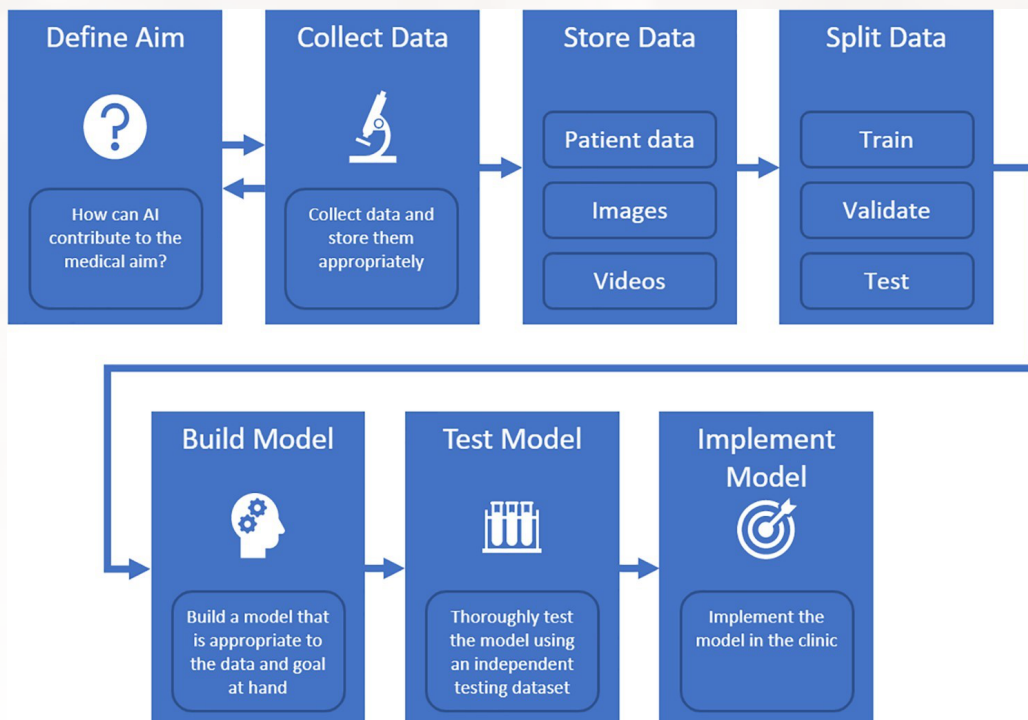


Why data?

Machine Learning (ML), a subfield of AI, refers to algorithms that automatically learn from data without being explicitly programmed. The following figure conveys us the typical approach for using AI models in ART clinics.

ML EXPLAINED:

Supervised and Unsupervised learning are subgroups of ML. In supervised learning, the answers are given for each observation. An observation within a dataset can be data from the ART cycles, such as an image of an embryo and the label regarding whether the embryo resulted in a pregnancy or not. The algorithm will learn from the dataset and the resulting ML model can predict pregnancy from another cycle with unknown labels.



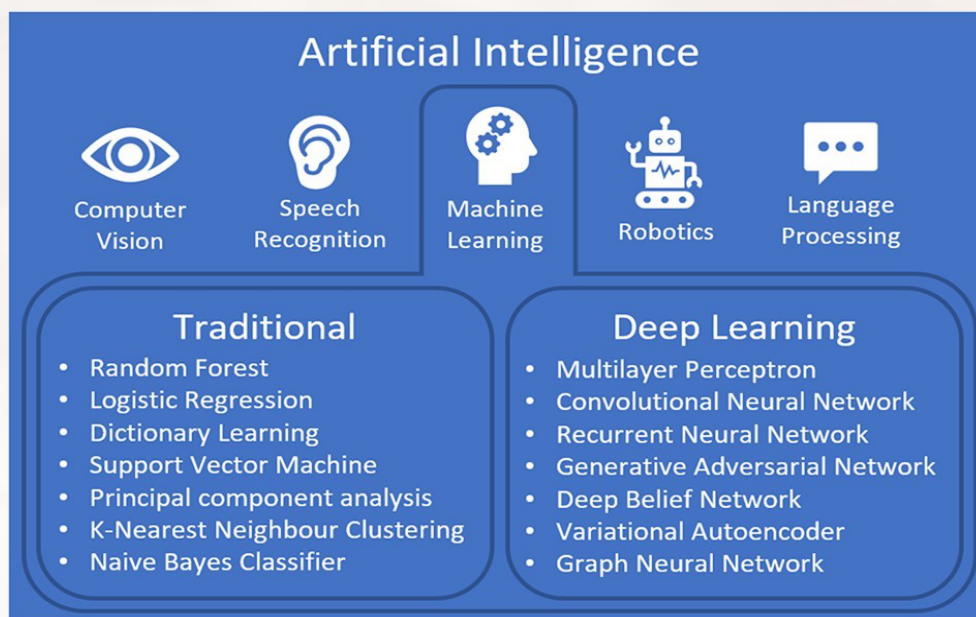
Unsupervised learning are the methods that search for patterns in unlabeled data automatically without any answers and the algorithm correlates the data and the outcomes based on the image characteristics by itself. Such visual features may be completely variable from what human observers can recognize or may see as relevant.

SUBFIELDS OF AI:

Machine Learning is the most relevant field for the development of the AI system of the health care. ML can be further classified as traditional and deep learning.

Artificial Neural Networks (ANNs) are a class of supervised learning. Deep Neural Networks (DNNs) or Deep Learning (DL) are subset of large and complex ANNs. These DL methods have the capability to learn from an unstructured data such as an image or a text.

The subfields largely rely on machine learning like computer vision and language processing. The overview of the common AI methods in use in ART is given in the figure below.



Hum Reprod, Volume 36, Issue 9, September 2021, Pages 2429–2442, <https://doi.org/10.1093/humrep/deab168>

DETAILS OF AI STUDIES RELATED TO ART:

The American Society for Reproductive Biology (ASRM) and European Society for Human Reproduction and Embryology (ESHRE) have already reported on different applications of Machine Learning ranging from sperm identification and morphology, identifying empty follicles, predicting the stages of embryonic cells and the formation of blastocysts from oocytes, assessing the quality of human blastocysts, predicting live births following embryo transfer, improving the selection of embryos, and defining optimal IVF stimulation protocols.

Majority of the studies that are being conducted utilizing the AI algorithms make use of Deep Learning and a very few utilize the Traditional Learning method. It has been shown that deep learning algorithms have performances similar to the healthcare professional, and also it has been reported that ML applications might perform better than healthcare professionals, but validation and prospective clinical studies are necessary to confirm those results. Most of those algorithms are for pattern recognition and suggest dichotomous (yes/no) diagnostic decisions, leading to sporadic implementation and use to support clinical and therapeutic decisions. None of these tools are broadly available and only work on selected platforms or setups. It has been shown that predictive models built on data and domain-specific knowledge can support and improve or solve specific problems. Let's see a few of the AI models and the studies that are being done with them in the following tables.



TABLE I

Overview of studies using AI-methods in embryo assessment and selection, and for prediction before treatment.

Year	Study	Aim of the study	Outcome	Dataset	AI methods	Summary answer
2019	Kanakasabapathy et al.	Develop inexpensive platforms for use in a stand-alone optical system and a smartphone-based optical system for automated grading of embryos based on images.	Classification of embryos based on cell morphology.	A retrospective dataset containing 160 embryo images from a stand-alone optical system and 385 embryo images from a smartphone-based optical system. Models were pretrained on other high-quality embryo data.	Deep Learning (CNN)	Two systems were developed for grading embryos (stand-alone imaging system and smartphone optical system). Both systems achieve an accuracy above 90%.
2019	Khosravi et al.	Develop an AI model for accurate prediction of blastocyst quality and selection for single embryo for transfer.	Classification of embryos into poor-quality and good-quality.	A retrospective dataset containing 12,001 time-lapse images at 110 hr post-insemination from 10,148 embryos. Manual classification by embryologists. Age of patient was included in the model for 2,182 embryos. Two external datasets were used for validation.	Deep Learning (CNN)	AI model (STORK) predicted blastocyst quality with an AUC above 0.98. The model achieved an AUC of 0.90 and 0.76 respectively on two datasets from other clinics.
2019	Qiu et al.	Prediction of a clinical model for estimating the cumulative live birth chance of the first complete IVF cycle using pre-treatment variables including BMI and AMH.	Cumulative live birth chance before IVF.	A retrospective dataset containing age, AMH, BMI, duration of infertility, previous live birth, previous miscarriage, previous abortion, and type of infertility.	Traditional ML (Logistic Regression, Random Forest, XGBoost, Support Vector Machine)	Four machine learning models were tested, of which XGBoost achieved the best score with an AUC of 0.73. The results indicate that BMI and AMH have a significant impact on live birth.
2020	Chavez-Badiola et al. (a)	Evaluate AI model performance for prediction of ploidy and implantation compared to trained embryologists.	Embryo ranking, embryo ploidy.	A retrospective dataset containing single timepoint images from 840 embryos at day 5 or 6 after fertilization by ICSI. Ploidy, hCG results, or both were known.	Deep Learning (Multilayer Perceptron)	An AI model (ERICA) was able to identify and rank blastocysts with the best potential from one image with higher accuracy than embryologists.
2020	Ver Milyea et al.	Predict embryo viability using images captured by optical light microscopy.	Implantation rate—foetal heartbeat.	A retrospective dataset containing light microscopy images of blastocysts, clinical outcome.	Deep Learning (Convolutional Neural Network)	An AI model (Life Whisperer) was tested on three independent testing datasets, where it achieved a 70.1% sensitivity for viable embryos and a specificity of 60.5% for non-viable embryos.
2021	Bori et al.	Develop an AI model for prediction of live birth based on blastocyst morphology and proteomic profile of culture media.	Prediction of live birth.	A retrospective dataset containing single time point images at 111hr +/- 1.5hr from 212 patients. 186 embryos after exclusions (131 non PGT from oocyte donation programme, 55 PDG with proteomic profile.	Deep Learning (Multilayer Perceptron)	Three AI models using both morphological and proteomic variables. The best model predicted live birth with an AUC of 1.0.

AI, Artificial intelligence; CNN, Convolutional neural network; AUC, Area under the curve; IVF, In vitro fertilization; ICSI, Intracytoplasmic sperm injection; ZP, Zona pellucida; PN, Pronucleus; PGT, Preimplantation genetic testing; AMH, Anti-Mullerian hormone; BMI, body mass index.

TABLE II**Overview of studies using AI-methods in semen analysis and selection of sperm for ICSI.**

Year	Study	Aim of the study	Outcome	Dataset	AI methods	Summary answer
2019	Agarwal et al.	Evaluate the performance of an automated AI system (LensHook) to measure sperm concentration and sperm motility.	Sperm concentration and sperm motility	A prospective dataset containing images and video from 135 semen samples.	No information available	Concentration and motility analysed by LensHook were comparable to manual assessment.
2020	Ilhan et al.	Fully automated analyses of sperm morphology by a smartphone-based system and introduce a new dataset.	Sperm morphology	200 retrospective images of stained sperm cells from 17 subjects (SMIDS dataset). Sperm cells were manually classified as normal or abnormal.	Deep learning (CNN) and traditional ML (Support Vector Machine, Decision Trees, K-Nearest Neighbours)	The most precise model was able to predict normal or abnormal sperm with an accuracy of 87%.
2021	Abbasi et al.	Improve AI models for classification of the sperm head, vacuoles, and acrosome as normal or abnormal.	Sperm morphology	1,540 retrospective images from the MHSMA dataset.	Deep learning (CNN)	Both AI models were able to predict sperm head characteristics more accurately than models previously described in other studies.

AI, Artificial intelligence; CNN, Convolutional neural network; CASA, Computer-assisted semen analysis.

APPLICATIONS OF AI IN INFERTILITY:

Data-driven solutions might help detect early indicators of infertility allowing an earlier identification of potential patients to refer for treatment as well as support doctors during a consultation to define a precise treatment strategy, providing estimations of success in terms of pregnancy and take-home baby rates.

Before starting treatment, we may also be able to define the best protocol of stimulation to apply for each patient to maximize success. We can also define the need of adjusting drugs and doses, during treatment, based on real-time biomarkers of follicle development. In the embryology and andrology laboratories, we could use data-driven solutions to evaluate gamete viability, embryo implantation potential, and uterine receptivity status before embryo transfer, therefore allowing us to target defined windows of implantation potential. Finally, we may be able to provide individualized support for the luteal phase. All this would allow the improvement of

pregnancy while reducing the time to achieve a healthy live birth.

In summary, widely accepted clinically relevant endpoints to target are as follows: (1) the birth of a single and healthy baby, (2) decrease of miscarriages, (3) higher implantation and clinical and ongoing pregnancy rates, (4) objective assessments of cytoplasmic and genetic health of gametes and embryos, and (5) standardization of operator assessments.

DOWNSIDES OF AI:

The AI algorithms are only as good as the data they are based on. There are limitations regarding generalisability due to difficulties with the standardisation of the ML methods. Variation in patient demographics, clinical and laboratory practices may cause data bias. When an AI model is based on training in one clinic, the AI model should be validated in independent cohorts. Furthermore, the models should not be limited to strict inclusion criteria, and optimally



the datasets should contain data from different clinics where testing data should be from a different site than the training and validation data.

Another important issue is that patient data and treatment information are not easily obtained for research due to data privacy and ethical considerations. This naturally limits the amount of patient related data to be used for training the AI model. DL methods, which are especially suited for image and video classification, require a large amount of diverse data to be generalisable.

Another weakness for some studies is that the data used for training are not connected to any treatment outcome, leading to overly complex models that might only detect irrelevant correlations. This can raise concerns like, for example, whether the prediction is related to the embryo implantation potential. Moreover, most articles resort to a positive heartbeat at ultrasound control or even a positive HCG test as their outcome, but the most important outcome in ART is the birth of a living, healthy child.

AI models are usually evaluated using different metrics such as accuracy, precision and sensitivity. Often only a small subset or even just a single metric is used to decide if the model performs well. This is not sufficient, and to make a proper estimation about the performance, a set of metrics needs to be considered. It might even be necessary to develop task specific performance measurements.

CONCLUSION:

Several studies have applied ML in ART, some of them focusing on clinical relevance, while others concern AI methodological aspects. The limitations are often small datasets and the use of AI algorithms not specifically designed for the fertility clinic. Large open datasets and methods specifically developed and tailored for use in context with ART could lead to better results and understanding.

For AI to significantly impact ART, the model must be developed in the context of clinical practice. Critical steps are proper evaluation and testing of AI systems in relation to outcomes and regulations, a better understanding of the technical aspects, and

determination of the performance of AI models regarding practical value in the clinic. In addition, it is important to standardise the use of AI in ART to enable more transparent, comparable, and reproducible results.

Additionally, a more systematic recording process should be implemented to automatize tasks such as identify unusual or outlier laboratory results. A robust predictive algorithm that provides probability estimations needs to be trained, tested, and properly validated in randomized clinical trials, to support clinically relevant data-driven decisions. Eventually, it is important to consider potential ethical issues and develop a friendly user interface for healthcare providers to facilitate the use of such a system.

REFERENCES:

1. Artificial intelligence in the fertility clinic: status, pitfalls and possibilities M A Riegler, M H Stensen, O Witczak, J M Andersen, S A Hicks, H L Hammer, E Delbarre, P Halvorsen, A Yazidi, N Holst ... Show more Human Reproduction, Volume 36, Issue 9, September 2021, Pages 2429–2442, <https://doi.org/10.1093/humrep/deab168>
2. AI in the treatment of fertility: key considerations Jason Swain,¹ Matthew Tex VerMilyea,² Marcos Meseguer,³ Diego Ezcurra, corresponding author⁴ and Fertility AI Forum Group
3. Agarwal A, Panner Selvam MK, Ambar RF. Validation of LensHooke® X1 PRO and computer-assisted semen analyzer compared with laboratory-based manual semen analysis. *World J Mens Health* 2021;39:e7.
4. Bori L, Dominguez F, Fernandez EI, Del Gallego R, Alegre L, Hickman C, Quinonero A, Nogueira MFG, Rocha JC, Meseguer M. An artificial intelligence model based on the proteomic profile of euploid embryos and blastocyst morphology: a preliminary study. *Reprod Biomed Online* 2021;42:340–350.
5. Bormann CL, Thirumalaraju P, Kanakasabapathy MK, Kandula H, Souter I, Dimitriadis I, Gupta R, Pooniwala R, Shafiee H. Consistency and objectivity of automated embryo assessments using deep neural networks. *Fertil Steril* 2020b;113:781–787.



**DR.KASTHURI.C , DGO., DNB. (OBG),
DR KASTHURI MATERNITY CLINIC, TRICHY.**

**PREGNANCY IN PARTIAL EMPTY SELLA SYNDROME
“ A CASE OF PRIMARY AMENORRHEA”**

INTRODUCTION

Empty Sella (ES) is a rare pituitary disorder characterised by pituitary herniating and flattening with a partial or total filling of the sella turcica area by cerebrospinal fluid. [1] When the pituitary gland shrinks or flattens, it cannot be detected on an MRI scan, giving the appearance of an empty sella. This is known as the EMPTY SELLA SYNDROME. The partial empty sella syndrome (PESS) indicates that a portion of the pituitary gland may be seen on the MRI image. [2] It is classified into two types: Primary and secondary. In Primary, the hole in the diaphragmatic sella covering the pituitary allows fluid to enter; it presses on the pituitary due to idiopathic origin (increase in CSF pressure). When the pituitary gland is injured by a tumour, surgery, or radiation therapy, Secondary empty sella syndrome develops. [3] Failure to attain menarche is a defining characteristic of Primary amenorrhea. The patient should be evaluated if there are no secondary sex traits by the time they are 13 years old, if menarche has not happened five years after the first signs of breast development, or if they are 15 years or older. [4]

ASRM classifies the causes of PRIMARY AMENORRHEA, and ESS is classified as CLASS V-B. PESS has also been linked to several endocrine autoimmune disorders and obesity. Patients with PES have been linked to risk factors such as type 2 diabetes, hypertension, drug use, and a history of pseudotumor cerebri. PES may be accelerated by pregnancy and postpartum pituitary necrosis (Sheehan's syndrome). [2] The pituitary hormone prolactin is involved in several reproductive processes. Prolactin secretion inhibits the release of gonadotropin-releasing hormone, which in turn affects the release of pituitary hormones necessary for the function of the gonadal

organs.[4] Amenorrhea was divided into three categories by the World Health Organization (WHO). Women in WHO group I don't show any signs of producing endogenous estrogen, have normal or low FSH and prolactin levels, and no abnormalities in the hypothalamic-pituitary area. Women in WHO group II can manufacture estrogen and have normal prolactin and FSH levels. Women in WHO group III have elevated FSH levels, which point to insufficient or failing gonads. [5] [6]

A pelvic ultrasound should be performed to determine whether a uterus is present. Unless the history and physical examination suggest otherwise, initial laboratory testing can identify the blood levels of follicle-stimulating hormone (FSH) and luteinising hormone (LH). This can assist in distinguishing between hyper gonadotropic and hypogonadotropic types of hypogonadism. The diagnosis of hypogonadotropic hypogonadism can be established if the screening FSH level is low. Measurements of serum thyroid-stimulating hormone and serum prolactin levels are two additional crucial blood tests. A high level of FSH in the serum implies early ovarian insufficiency or failure. Patients under the age of 30 should undergo a karyotype. [4] Pituitary gland volume changes, such as hyperplasia during pregnancy and breastfeeding and pituitary involution after menopause, may also contribute to the pathophysiology of empty sella syndrome, explaining the condition's noticeably greater incidence in female patients. An empty sella is usually unintentionally found when undergoing an MRI or CT scan or while being examined for headaches, endocrine, neurological, or visual abnormalities. It is seen less frequently if further imaging is done in response to aberrant sella turcica radiographs. [7]



This case report highlights a distinctive clinical scenario of a patient with primary amenorrhea associated with PESS. The successful management and subsequent achievement of pregnancy through ovulation induction and IUI underscore the significance of early recognition and personalised interventions for patients facing reproductive challenges related to PESS.

CASE REPORT

In this case report, we presented the details of a 28-year-old woman who presented with primary amenorrhea and was subsequently diagnosed with partial empty sella syndrome. Upon evaluation, it was observed that she had normal stature but lacked breast development (TANNER stage I), No axillary hair, and pubic hair. The patient's hormonal profile revealed low levels of follicle-stimulating hormone (FSH) (<0.6 mIU/mL), estradiol (E2) (<1.06 pg/mL), and luteinising hormone (LH) (0.10 mIU/mL), suggesting potential ovarian dysfunction and hormonal imbalance. The thyroid-stimulating hormone (TSH) was elevated (11.45 mIU/L), indicating hypothyroidism, while prolactin (PRL) (10.9 ng/mL) fell within the normal range. Serum cortisol (1.04 mcg/dL) required further interpretation based on specific reference ranges. Hormonal profiling revealed a hypogonadotropic pattern and further confirmation was obtained through magnetic resonance imaging (MRI) which showed a thin infundibulum, small adenohypophysis, and a normal neurohypophysis. Karyotyping confirmed a 46XX chromosomal pattern.

Additional investigations, including an ultrasound examination, revealed a small uterus measuring 4.5 x 1.2 x 2.3 cm, small ovaries measuring 1 x 1.2 cm, and a thin endometrium measuring 3 mm. Based on these findings, partial empty sella syndrome was diagnosed. The patient was started on a regimen of cyclical estrogen, progesterone, steroids, and levothyroxine to address the hormonal imbalance and induce regular menstrual cycles. This resulted in the restoration of menstrual regularity and an increase in endometrial thickness up to 5 mm.

Following successful ovulation induction using follicle-stimulating hormone (FSH) and intrauterine insemination (IUI), the patient conceived. Throughout the antenatal period, she received antenatal steroids and levothyroxine under the supervision of an endocrinologist. Delivery was performed via elective

cesarean section, which gave birth to a healthy baby girl weighing 2.4 kg, with an APGAR score of 9/10. Intraoperative parenteral steroids were administered during the cesarean section, and both the mother and baby had an uneventful postoperative course.

DISCUSSION

A case of primary amenorrhea in a 28-year-old woman was evaluated for hypogonadotropic hypogonadism and diagnosed as "partial empty sella syndrome".

In our case report, the uterus is measured at 4.5 x 1.2 x 2.3 cm. These dimensions suggest a small-sized uterus. The ovaries measure 1 x 1.2 cm, indicating relatively small-sized ovaries. Small ovarian size may have implications for ovarian function and fertility potential. A thin endometrium may indicate a potential issue with the lining of the uterus, which could affect fertility or menstrual cycles. The Sella, which houses the pituitary gland, is reported as normal. This indicates the absence of any significant abnormalities or structural changes in this region. The thin infundibulum may or may not have any clinical significance on its own. This finding suggests a potential alteration in the size or function of the anterior pituitary. The neurohypophysis, the posterior part of the pituitary gland involved in storing and releasing hormones, is reported as normal. This indicates no apparent abnormalities in the posterior pituitary. Based on the findings, the patient has been diagnosed with Partial Empty Sella Syndrome. This condition is characterised by a partially empty sella turcica, the bony structure housing the pituitary gland. It is typically an incidental finding in imaging studies and may or may not be associated with hormonal abnormalities or clinical symptoms. The patient's karyotype is reported as 46XX, indicating a typical female chromosomal pattern.

The FSH level is low, suggesting a possible issue with the pituitary gland or FSH release inhibition. The E2 level is also low, indicating reduced estrogen production, which can impact reproductive function. Elevated TSH levels suggest a potential underactive thyroid, leading to various symptoms. The PRL level is normal. A low LH level suggests a potential issue with the pituitary gland or hormonal imbalance. The cortisol level is within the normal range, but further evaluation is required to interpret its significance fully. Compared to prolactinomas, which have values higher than 200 ng/ml, the degree of hyperprolactinemia

reported in empty sella syndrome is modest (often less than 100 ng/ml). [8]Ghatnatti et al. [9] noted endocrine dysfunction in 50% of PESS patients with hyperprolactinemia as the most common endocrine abnormality. Here our patient has normal prolactin levels. According to Tulandi et al., a 31-year-old lady who underwent a cesarean section experienced significant hemorrhage and hypotension. She was diagnosed with diabetes insipidus seven months after developing polyuria, and a brain MRI revealed an empty sella. [10] According to Dutta et al., a 27-year-old male with symptoms of hypothyroidism was identified with an empty sella on an MRI and had complete symptom relief after starting levothyroxine medication. [11] In a case study, an MRI of the brain and sella showed that the sella was mostly filled with CSF. The pituitary gland had concave upper margins and seemed thinner. It's speculative whether the enlarged sella turcica is caused by intrasellar herniation of the suprasellar subarachnoid space with compression of the pituitary gland or whether there was prior pituitary gland enlargement due to primary hypothyroidism, followed by atrophy from treatment with l-thyroxine, and then an extension of subarachnoid space into the sella turcica. [2]

In research by Guitelman et al., 28% of the patients had it. 40% of these individuals had panhypopituitarism, whereas 60% of hypopituitary patients had partial or isolated hormone deficits. [12] A pooled meta-analysis of 4 studies found that 52% of participants had hypopituitarism. 30% of individuals with PES had several pituitary hormone deficits, whereas 21% had isolated ones. The two most prevalent isolated deficiencies were growth hormone and gonadotropins. [13] The study's findings revealed a significant lack of attention given to evaluating the hormonal profile of patients with partial empty sella syndrome (PES). Only a small proportion of patients thoroughly assessed their pituitary hormone levels. Additionally, the study observed that most patients diagnosed with PES presented with concurrent deficiencies in one or multiple hormones at the time of initial evaluation. This simultaneous presence of hormonal deficiencies posed a challenge in tracking the sequential progression of hormone deficiencies in these patients. [1]

According to research studies, growth hormone deficit is the most prevalent endocrine abnormality in PES.[9]Poggi and colleagues conducted a study on patients with PES to investigate the occurrence of

growth hormone deficiency and its clinical implications. Their findings revealed a notable prevalence of GH deficiency, underscoring the significance of screening for this condition in PES patients.[14] In a study, Twenty-two patients (10% of all patients); 18 women, (11% of all women) had hyperprolactinemia at the time of their initial visit. Six of these patients were postmenopausal, while 12 of the ladies were premenopausal and had oligomenorrhea. Galactorrhea affected six people. [15] In a patient study conducted two years following the beginning of hypopituitarism, radiographic tests indicated a normal-sized empty sella.[16]Fleckman et al. (1983) found that 11 out of 13 individuals with Sheehan's syndrome had empty sellas that were the typical size.[17]

The fact that posterior pituitary involvement is less common than anterior pituitary is partly explained by the vascular supply in the two regions. [16/17]

These findings highlight the need for a comprehensive evaluation and individualised treatment to address the underlying causes and potential impact on reproductive function and overall hormone balance.

CONCLUSION

In conclusion, this case report exemplifies the potential for solving the puzzle of reproductive endocrinology and infertility through a comprehensive clinical approach, ultimately providing hope and a positive outcome for patients seeking to achieve pregnancy.

REFERENCE:

1. Ekhzaimy AA, Mujammami M, Tharkar S, Alansary MA, Al Otaibi D. Clinical presentation, evaluation and case management of primary empty sella syndrome: a retrospective analysis of 10-year single-centre patient data. *BMC Endocrine Disorders*. 2020 Dec;20(1):1-1.
2. Aruna, P., Sowjanya, B., Reddy, P. A., Krishnamma, M., & Naidu, J. N. (2014). Partial empty sella syndrome: a case report and review. *Indian Journal of clinical biochemistry: IJCB*, 29(2), 253–256. <https://doi.org/10.1007/s12291-013-0369-1>
3. Melmed S, Kleinberg D, Ho Ken . Pituitary physiology and diagnostic evaluation. In: Kronenberg HM, Melmed S, Polonsky KS, Larsen PR, editors. *Williams textbook of endocrinology*, Chap 8. 12. Philadelphia: Elsevier; 2011.
4. Gasner A, Rehman A. Primary Amenorrhea. [Updated 2023 Mar 30]. In: StatPearls [Internet]. Treasure Island (FL): StatPearls Publishing; 2023 Jan-. Available from:



<https://www.ncbi.nlm.nih.gov/books/NBK554469/>

5. Yang P, Liu X, Gao J, Qu S, Zhang M. Complete androgen insensitivity syndrome in a young woman with metabolic disorder and diabetes: A case report. *Medicine (Baltimore)*. 2018 Aug;97(33):e11353
6. Wei HL, Lu S, Wang XL, Li JW, Cui YP, Yao YS. [17 β -Hydroxylase deficiency with severe hypertension as the initial symptom in a child]. *Zhongguo Dang Dai Er Ke Za Zhi*. 2018 Aug;20(8):675-679.
7. Miljic D, Pekic S, Popovic V. Empty Sella. [Updated 2021 Aug 1]. In: Feingold KR, Anawalt B, Blackman MR, et al., editors. *Endotext* [Internet]. South Dartmouth (MA): MDText.com, Inc.; 2000-. Available from: <https://www.ncbi.nlm.nih.gov/books/NBK532084/>
8. Gharib Hossein, Frey Harald M, Laws Edward R, Randall Raymond V, Scheithauer Bernd W. Coexistent Primary Empty Sella Syndrome and Hyperprolactinemia. Report of 11 cases. *Arch Intern Med*. 1983;143(7):1383-1386.
9. Ghantnatti V, Sarma D, Saikia U. Empty sella syndrome-beyond being an incidental finding. *Indian J Endocr Metab*. 2012;16(suppl2):321-323
10. Tulandi T, Yusuf N, Posner BI. Diabetes insipidus: a postpartum complication. *Obstet Gynecol*. 1987;70(3):492-495
11. Dutta D, Maisnam I, Ghosh S, Mukhopadhyay P, Mukhopadhyay S, Chowdhury S. Panhypopituitarism with empty sella a sequel of pituitary hyperplasia due to chronic primary hypothyroidism. *Indian J Endocr Metab*. 2012;16(Suppl2):282-284.
12. Guitelman M, Basalvibaso NG, Vitale M, Chervin A, Katz D, Miragaya K, Herrera J, Cornalo D, Servido M, Boero L, Manavela M, Danilowicz K, Alfieri A, Stalldecker G, Glerean M, Fainstein Day P, Ballarino C, Mallea Gil MS, Rogozinski A. Primary empty sella (PES): a review of 175 cases. *Pituitary*. 2013;16:270-274.
13. Auer MK, Stieg MR, Crispin A, Sievers C, Stalla GK, Kopczak A. Primary empty sella syndrome and the prevalence of hormonal dysregulation. *DeutschesArzteblattInternational*. 2018;115:99-105
14. Poggi M, Monti S, Lauri C, Pascucci C, Bisogni V, Toscano V. Primary empty Sella and GH deficiency: prevalence and clinical implications. *Ann Ist Super Sanita*. 2012;48(1):91-6.
15. De Marinis L, Bonadonna S, Bianchi A, Maira G, Giustina A. Primary empty sella. *The Journal of Clinical Endocrinology & Metabolism*. 2005 Sep 1;90(9):5471-7.
16. OKADA K, ISHIKAWA SE, SAITOT, KUMAKURA S, SAKAMOTO Y, KUZUYA T. A case of partial hypopituitarism with empty sella following normal course of pregnancy and delivery. *Endocrinologia japonica*. 1986;33(1):117-23.
17. Fleckman, A. M., U. K. Schubart, A. Danziger and N. Fleischer (1983). Empty sella of normal size in Sheehan's syndrome. *Am.J. Med.* 75, 585-591.



Neonatal Intensive Care Unit

Has one of the most advanced tertiary care, Level 3 NICU, With 30 Beds

OUR FACILITIES



The family centric NICU is a first of its kind, where both parents & doctors together participate in the treatment and care of the child



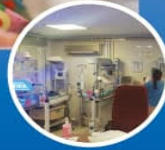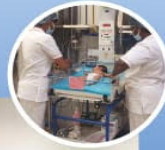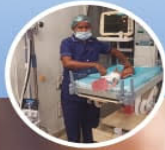Trained and compassionate health care staff to provide developmental care for preterm and low birth weight neonates



Range of ventilator support to provide conventional and advanced life-saving treatment



Non Invasive Ventilator



Invasive Ventilator



24/7 Senior consultant presence on site



High Flow Oxygen Therapy



Bubble -C -Pap,

MARUTI HOSPITAL

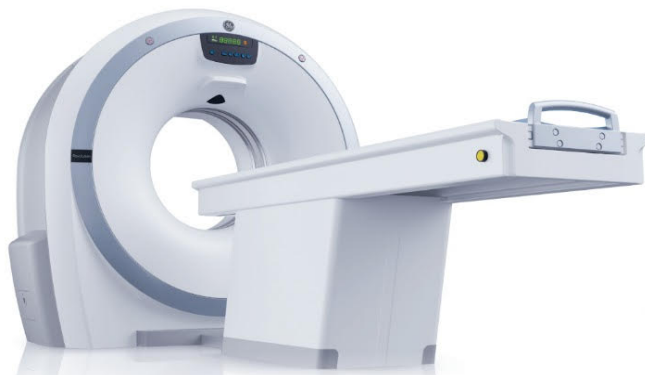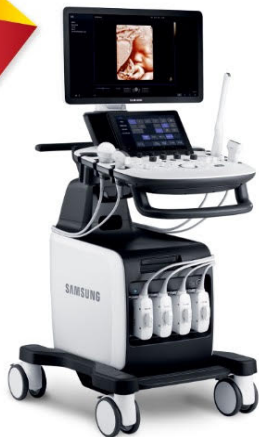95, Pattabiraman Steet, Tennur, Trichy - 17. 📞 0431 - 2240000, For Appointment: 8489696111, For Ambulance : 94860 13333, info@marutihospital.in | www.marutihospital.in

Dr. G. Karthika Vignesh, MD., (RD),
Consultant Radiologist

Dr. S. Sowmiya, MD., (RD),
Consultant Radiologist



Healing Begins Here



FACILITIES

- ◆ Advanced Multislice-CT
- ◆ CT Angiography
- ◆ Hysterosalpingogram (HSG)
- ◆ Color Doppler
- ◆ Ultrasound Scan
- ◆ Fetal Ultrasonogram
- ◆ Sono Mammogram
- ◆ Orthopantogram
- ◆ ECHO
- ◆ ECG
- ◆ X Ray
- ◆ Master Health Checkup
- ◆ Lab

OPEN ON ALL SUNDAYS
TIME : 09.00 AM TO 03.00 PM

📍 C-109, 5th Cross, Thillainagar East, Fort Station Road, Trichy - 18. Call : 0431 3553998, 9169 578 578

✉ trichyvividiagnostics@gmail.com 🌐 trichyvividiagnostics.com



**DR. RAJA ILAVARASI MBBS, MS, DNB OG, FRM
DR. KARTHIK SENTHILVEL MBBS, MDRD, PDF
MS HOSPITAL, TRICHY**

CLINICAL UPDATES IN THE DETECTION OF PRE-ECLAMPSIA – AN OVER VIEW BY AN OBSTETRICIAN AND FETAL MEDICINE CONSULTANT

Pre-eclampsia (PE) is associated with severe maternal and perinatal morbidity and mortality. According to the National Eclampsia Registry (NER), the incidence of pre-eclampsia in our country is 10.3% with eclampsia contributing to 1.9%. The maternal mortality with eclampsia is 4-6%^{1,2}. Due to lack of adequate knowledge regarding the screening methods for pre-eclampsia, lack of combined detection methods to detect the risk for pre-eclampsia accurately and lack of multi-disciplinary approach, still, many preventable cases of pre-eclampsia are going undetected in our country. The aim of this article is to bridge this gap in our clinical practice.

ROLE OF MATERNAL HISTORY:

Evidence suggests that the administration of low dose aspirin, early in the first trimester prevents onset of pre-eclampsia by 62%. This requires an early detection of the "AT RISK" population. This is feasible with the GESTOSIS score that has been formulated by the FOGSI-GESTOSIS-ICOG committee.

- This score involves all the existing and emerging risk factors in the pregnant woman.
- Score 1, 2 and 3 is allotted to each clinical risk factor as per its severity in development of preeclampsia.
- With careful history and assessment of woman a total score is obtained time to time.
- When total score is ≥ 3 ; pregnant woman should be marked as 'At risk for Preeclampsia'¹.

But this method of scoring is only based on maternal history and has not included the risk factors of

defective placentation. Based on maternal history, only 45% of the "AT RISK" population can be detected to have PE before 37 weeks and only 50.2% of this population can be detected to have PE before 34 weeks³. Hence, integration of the blood pressure (BP) measurements, Uterine artery pulsatility index (UtA PI) and bio-markers will increase the prediction rate for these patients.

IDEAL METHOD OF BP MEASUREMENT:

The ideal blood pressure measurement has to be taken with the patient in sitting position and both the feet touching the ground; the arms have to be well supported at the level of her heart; An appropriate cuff size should be selected depending on the mid-arm circumference (small <22 cm, normal 22-32 cm, or large 33-42 cm). The blood pressure should be measured in both the arms simultaneously (Fig 1); series of recordings at 1-min intervals should be taken until they become stable (in the last two recordings the difference in systolic blood pressure should be less than 10 mmHg and the difference in diastolic blood pressure should be less than 6 mmHg). The Mean Arterial Pressure (MAP) of each arm should be calculated as the average of the last two stable measurements and the measurement from the arm with the highest final pressure should be used^{4,5}. This value is integrated with the other pre-eclampsia predictive factors. Maternal history, MAP and UtA PI without bio-markers have a detection rate of 66.8% in detecting PE before 37 weeks and only 42.2% for detection of PE after 37 weeks. These factors have a detection rate of 78% for PE before 34 weeks³.

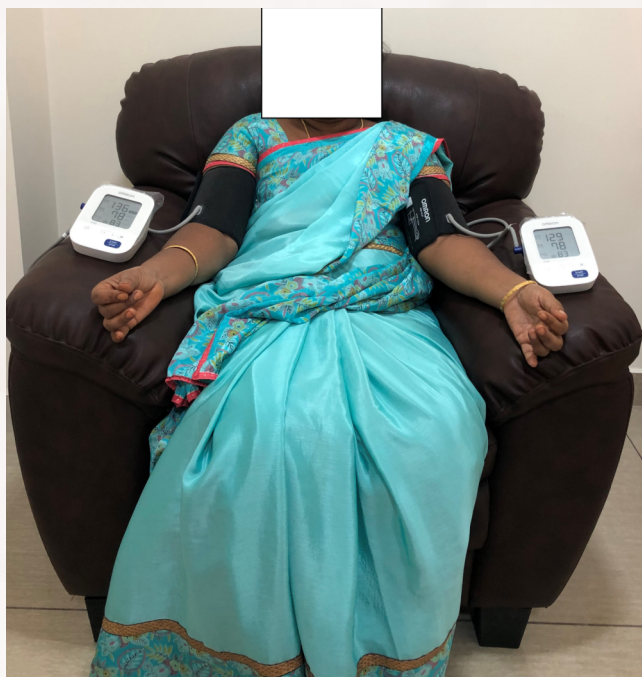

Fig 1: IDEAL METHOD OF BP MEASUREMENT

HOW TO MEASURE THE UTERINE ARTERY PI:

After identification of each uterine artery, pulsed wave doppler should be used with the sampling gate set at 2 mm to cover the whole vessel. Care should be taken to ensure that the angle of insonation is less than 30°. It is important to check that the peak systolic velocity is greater than 60 cm/s. This ensures that the uterine artery (not the arcuate artery) is being examined. When three similar consecutive waveforms are obtained the PI should be measured (Fig 2) and the mean PI of the left and right arteries is calculated⁶.

Pulsatility index = (Peak systolic velocity - minimum diastolic velocity) / Mean velocity.

The uterine artery mean PI should be considered as a percentile value plotted in a population specific graph rather than considering a single cut-off as mean PI to predict the high resistance in the uterine arteries. Screening by first-trimester uterine artery PI >90th centile alone has a detection rate of 48% for women who will develop early PE and 26% for those who will develop any PE, with a 10% screen-positive rate. Hence it has to be combined with the maternal history, MAP and bio-markers to increase the detection rate⁷. Regular audit of first trimester uterine artery PI measurements should be done with cumulative summation methods and target graphs⁸.

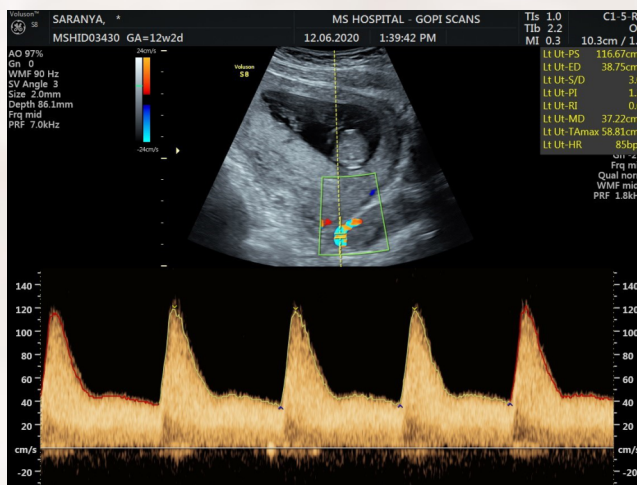


Fig 2: PULSE WAVE DOPPLER OF THE UTERINE ARTERY

IMPORTANCE OF DOUBLE MARKER IN PRE-ECLAMPSIA PREDICTION:

Pregnancy Associated Plasma Protein A (PAPP-A), which is a biomarker routinely included in the double test for aneuploidies has a significant detection rate for PE when combined with the above mentioned factors. Low PAPP-A in the first trimester is associated with poor placentation⁹. PAPP-A, maternal history, MAP and UtA PI have a detection rate of 78% to detect PE before 34 weeks, 67% to detect PE before 37 weeks and 42.3% to detect PE after 37 weeks³.

ROLE OF OTHER BIO-MARKERS:

Placental Growth Factor (PlGF) is a member of the vascular endothelial growth factor (VEGF) family and is pro-angiogenic in nature. Circulating PlGF concentrations gradually increase during normal pregnancy to reach a peak at, approximately 30 weeks of gestation. It decreases later in pregnancy because of binding with the soluble forms like tyrosine-kinase 1 (sFLT-1). In PE patients, the circulating levels of PlGF are comparatively low throughout the pregnancy because of the decreased expression from the placenta (poor placentation) and increased binding to sFLT-110. This also contributes to the abnormal growth of the fetus in the latter half of pregnancy in these PE women. PlGF, maternal history, MAP and UtA PI have a detection rate of 84% for detecting PE before 34 weeks, 74.1% for detecting PE before 37 weeks and 44% for detecting PE after 37 weeks (Table 1). Even if PAPP-A is added to this profile, it increases the detection rates very minimally, without much significance.

sFLT-1 is a splice variant of VEGF receptor 1 and an anti-



angiogenic factor that binds VEGF and PIGF. It is produced by the placenta in an hypoxic environment. In a normal pregnancy, sFLT-1 continues to rise till the end of the pregnancy. But, in PE women, the blood values start raising five weeks before the onset of PE and are abnormally elevated upto 43 times compared to normal women which is aggravated by the poor placentation¹¹. sFlt-1 measurements in plasma showed 89% diagnostic sensitivity and 90% specificity in early PE (at <34 weeks) as compared to 55% diagnostic sensitivity and 58% specificity in late PE (at >37 weeks)¹¹.

ROLE OF sFLT-1:PIGF ratio:

In the second trimester, when the sFLT-1:PIGF ratio was more than 38 it had a diagnostic accuracy of 90.8% (95% CI, 85.8%–95.7%) in detecting pre-eclampsia. Also, the negative predictive value (NPV) was 96.4% to rule-out preeclampsia within 7 days, and the positive predictive value (PPV) was 84.8% for predicting preeclampsia within 28 days¹². Compared with all the biomarkers that are available, estimation of plasma/urine level of PIGF and sFlt-1/PIGF ratio during mid-gestation is really a promising tool to detect PE.

PRE-ECCLAMP SIA	NT with UtA Doppler	Maternal history, MAP and UtA PI	Maternal history, MAP, UtA PI and PAPP-A	Maternal history, MAP, UtA PI and PIGF
PE < 34 weeks	48%	78%	78%	84%
PE 34- 37 weeks	26%	66.80%	67%	74%
PE >37 weeks	26%	42.20%	42.30%	44%

Table 1: DETECTION RATE OF VARIOUS SCREENING PARAMETERS FOR PRE-ECCLAMP SIA

BIO-MARKERS UNDER RESEARCH:

Glycosylated fibronectin, soluble Endoglin, Auto antibodies against angiotensin II type 1 (AT1) receptor, Placental Protein 13, Visfatin, Activin A and Inhibin A.

CONCLUSION:

Integration of bio-markers with the routine screening for pre-eclampsia will significantly improve the detection rate for pre-eclampsia, especially the early onset spectrum of cases. In a low income population, who is not affordable for the biomarkers of PE, integration of double marker (PAPP-A) with the maternal history, UtA PI and MAP will detect a significant number of pre-eclampsia patients. In a low resource setting, where there is scarce availability of biomarkers, GESTOSIS score with UtA PI and MAP can detect a good number of pre-eclampsia patients, who will otherwise go undetected. All the available screening options are less sensitive in detecting the high risk cases for late onset pre-eclampsia. In this group of patients, proper risk stratification in the first trimester with serial follow up in the second and third trimesters can be helpful.

REFERENCES:

1. FOGSI-GESTOSIS-ICOG, Hypertensive Disorders in Pregnancy, Good Clinical Practice Recommendations, 2019.
2. Jain M. Retrospective study to estimate gestosis score in high risk pregnant women and its clinical correlation.
3. Mazer Zumaeta A, Wright A, Syngelaki A, Maritsa VA, Da Silva AB, Nicolaidis KH. Screening for pre-eclampsia at 11–13 weeks' gestation: use of pregnancy-associated plasma protein-A, placental growth factor or both. *Ultrasound in obstetrics & gynecology*. 2020 Sep;56(3):400-7.
4. Poon LC, Zymeri NA, Zamprakou A, Syngelaki A, Nicolaidis KH. Protocol for measurement of mean arterial pressure at 11-13 weeks' gestation. *Fetal diagnosis and therapy*. 2012 Jan 13;31(1):42-8.
5. O'Gorman N, Wright D, Poon LC, Rolnik DL, Syngelaki A, de ALVARADO M, Carbone IF, Dutemeyer V, Fiolna M, Frick A, Karagiotis N. Multicenter screening for pre-eclampsia by maternal factors and biomarkers at 11–13 weeks' gestation: comparison with NICE guidelines and ACOG recommendations. *Ultrasound in Obstetrics & Gynecology*. 2017 Jun;49(6):756-60.
6. Gómez O, Figueras F, Fernández S, Bennasar M, Martínez JM, Puerto B, Gratacós E. Reference ranges for uterine artery mean pulsatility index at 11–41 weeks of gestation. *Ultrasound in Obstetrics and Gynecology: The Official Journal of the International Society of Ultrasound in Obstetrics and Gynecology*. 2008 Aug;32(2):128-32.
7. Bhide A, Acharya G, Baschat A, Bilardo CM, Brezinka C, Cafici D, Ebbing C, Hernandez-Andrade E, Kalache K, Kingdom J, Kiserud T. ISUOG Practice Guidelines (updated): use of Doppler velocimetry in obstetrics. *Ultrasound in*

obstetrics & gynecology: the official journal of the International Society of Ultrasound in Obstetrics and Gynecology. 2021 Aug;58(2):331-9.

8. Ridding G, Hyett JA, Sahota D, McLennan AC. Assessing quality standards in measurement of uterine artery pulsatility index at 11 to 13+6 weeks' gestation. *Ultrasound in Obstetrics & Gynecology*. 2015 Sep;46(3):299-305.
9. Luewan S, Teja-Intr M, Sirichotiyakul S, Tongsong T. Low maternal serum pregnancy-associated plasma protein-A as a risk factor of preeclampsia. *Singapore medical journal*. 2018 Jan;59(1):55.
10. Chau K, Hennessy A, Makris A. Placental growth factor and pre-eclampsia. *Journal of human hypertension*. 2017 Dec;31(12):782-6.
11. Kar M. Role of biomarkers in early detection of preeclampsia. *Journal of clinical and diagnostic research: JCDR*. 2014 Apr;8(4):BE01.
12. Miller JJ, Higgins V, Melamed N, Hladunewich M, Ma L, Yip PM, Fu L. Clinical validation of the sFlt-1: PIGF ratio as a biomarker for preeclampsia diagnosis in a high-risk obstetrics unit. *The Journal of Applied Laboratory Medicine*. 2023 May 1;8(3):457-68.



**DR. HARSHINI JAYAKUMAR MBBS DGO DNB
JANANI FERTILITY CENTRE, TRICHY**

ROLE OF VITAMIN-D AND INFERTILITY- A COMPREHENSIVE REVIEW

Introduction:

Infertility is a common issue affecting millions of couples worldwide. While several factors contribute to fertility struggles, emerging research suggests that vitamin D deficiency may be linked to infertility in both men and women. This article explores the relationship between vitamin D and infertility and highlights the importance of maintaining optimal levels of this essential nutrient for reproductive health.

VIT-D an overview

It is a steroid hormone. Vit D precursor 7 dehydrocholesterol is normal intermediary in cholesterol pathway and is present in skin (1)

Vit D from skin and diet is metabolised in the liver by the enzyme 25-hydroxylase to 25 (OH) D which is used to determine patients Vit d status.

Vit D sufficient >30 ng

Vit D insufficient- 20-29ng and vit -d deficient <20 ng/ml. (2)

Biological actions of vitamin D are mediated through Vit D receptor (VDR) that is distributed across various tissue including skeleton and parathyroid glands as well as reproductive tissues. (3)

In women VDR mRNA has been shown to be expressed in the ovaries (4)

It is present in mixed ovarian cells as well as in purified granulosa cell cultures - indicating a role in steroidogenesis of sex hormone (5)

It is also expressed in endometrium (4)

In men VDR was detected in human testicular tissue homogenates using titrated VIT-D (6)

Recently VDR was also detected in human sperm, with binding sites in the nucleus and also in mid pieces of

sperm (7)

Vit D and female fertility

Several studies have investigated the association between vitamin D and female fertility. A systematic review conducted by Lerchbaum and Obermayer-Pietsch in 2012 found evidence supporting a potential link between vitamin D deficiency and infertility. They noted that vitamin D levels influenced various aspects of female reproductive physiology, including menstrual regularity, ovulation, and embryo implantation. (8) Similar findings were reported in a meta-analysis by Muscogiuri et al. (2014), further emphasizing the importance of adequate vitamin D levels for optimum female fertility. (9)

In a study among 84 infertile women undergoing IVF, women with higher levels of 25(OH)D in serum and follicular fluid were significantly more likely to achieve clinical pregnancy following IVF, and high vitamin D levels were significantly associated with improved parameters of controlled ovarian hyperstimulation (10)

Anifandis et al. investigated 101 consecutive women who underwent 101 IVF-intracytoplasmic sperm injection (ICSI) ovarian stimulation cycles. In this study, women with a sufficient vitamin D status (25(OH)D 30 ng/ml in follicular fluid) had a lower quality of embryos and were less likely to achieve clinical pregnancy when compared with women with insufficient (follicular fluid 25(OH)D 20.1-30 ng/ml) or deficient vitamin D status (follicular fluid 25(OH)D (20 ng/ml). (11)

Rudick et al. (2012) conducted an evidence-based review focusing on the impact of vitamin D deficiency on reproductive outcomes in women. The review highlighted the association between low vitamin D levels and an increased risk of conditions such as polycystic ovary syndrome (PCOS), endometriosis, and recurrent pregnancy loss. (12)

PCOS is the most common cause of anovulatory infertility in women.

There is evidence suggesting that vitamin D deficiency might be involved in the pathogenesis of insulin resistance and the metabolic syndrome in PCOS

a study among 100 women with PCOS from Turkey, the authors observed a correlation of 25(OH)D levels with testosterone and DHEAS levels and the LH/FSH ratio (13).

vitamin D deficiency was found to be more common in PCOS women than in controls in an Iranian cohort including 85 PCOS and 115 control women (14),

As obesity is related to insulin resistance in PCOS (15) as well as in healthy subjects, the association of obesity with vitamin D deficiency deserves further discussion.

Wortsman et al. (16) demonstrated that the increase of 25(OH)D levels 24 h after whole-body u.v.-light exposure was 57% lower in obese compared to that in nonobese subjects (17) suggesting low circulating vitamin D levels due to trapping of vit D in fat tissues.

Interestingly, it has been shown in a randomized controlled trial (RCT) in 40 PCOS patients who had 12-week treatment with atorvastatin at a dose of 20 mg daily resulted in a significant increase in serum 25(OH)D concentrations that was independent of the lipid-lowering effect of atorvastatin (18).

In a study among 60 infertile PCOS women, metformin treatment combined with calcium and vitamin D supplementation resulted in a higher number of dominant follicles when compared with metformin alone and placebo, which might indicate a beneficial effect on fertility (19) association of 25(OH)D levels with metabolic and endocrine parameters in PCOS women as well as the promising results from intervention studies in PCOS women might lead to a recommendation for measuring 25(OH)D and for vitamin D supplementation to improve fertility as well as metabolic disturbances.

and also suggesting vitamin D deficiency may improve the success rates of infertility treatments and enhance overall reproductive health in women.

Vit D and male fertility:

While the majority of research has focused on females, there is also evidence suggesting a link between vitamin D and male fertility. Hammoud et al. (2012)

examined the association between vitamin D levels and semen quality in men. The study found that men with sufficient vitamin D levels exhibited healthier semen parameters, including sperm count, motility, and morphology (20). This suggests that optimizing vitamin D levels may have a positive impact on male reproductive function and fertility.

Blomberg Jensen et al. (21) studied the association of semen quality and vitamin D status in a cross-sectional study including 300 men from the general population. The authors found a positive correlation of 25(OH)D serum levels with sperm motility and progressive motility. Moreover, men with vitamin D deficiency (110ng/ml) had a lower proportion of motile, progressive motile, and morphologically normal spermatozoa compared with men with sufficient vitamin D status (030ng/ml).

Vit D supplementation:

To date, there are no specific guidelines regarding vitamin D supplementation for women or men affected by endocrine disturbances including infertility or hypogonadism. Thus, we will briefly discuss recent recommendations by the Endocrine Society (22).

Endocrine Society Clinical Practice Guideline (2011, updated in 2018):

- Recommends a vitamin D intake of 600-2000 IU per day for most adults, depending on baseline vitamin D levels.

- For individuals at risk of vitamin D deficiency (such as those with limited sun exposure or certain medical conditions), higher doses of up to 4000 IU per day may be required under medical supervision.

In general, vitamin D supplementation with 1000 IU/day increases 25(OH)D levels per 10 ng/ml (23). Importantly, vitamin D intoxication results in hypercalcemia, renal damage, and vascular calcification but is not observed until 25(OH)D levels reaches 150ng/ml(1).

Conclusion:

In conclusion, growing evidence suggests that vitamin D may have a significant influence on fertility in both women and men. Adequate vitamin D levels are essential for optimal reproductive function, with deficiency being associated with negative



reproductive outcomes. Further research is needed to fully understand the mechanisms underlying the role of vitamin D in fertility and to explore the potential benefits of vitamin D supplementation in improving reproductive health and We want to emphasize the fact that in infertility cases drastic improvements in reproductive failure may not be achieved by vitamin D treatment alone. Nonetheless, ensuring sufficient vitamin D levels through sun exposure, dietary intake, or supplementation may be a safe and valuable strategy for individuals seeking to enhance their fertility.

References:

- Holick MF. Vitamin D deficiency. *New England Journal of Medicine* 2007 357 266–281. (doi:10.1056/NEJMr070553)
- The Endocrine Society, the National and International Osteoporosis Foundation, and the American Geriatric Society
- Kinuta K, Tanaka H, Moriwake T, Aya K, Kato S & Seino Y. Vitamin D is an important factor in estrogen biosynthesis of both female and male gonads. *Endocrinology* 2000 141 1317–1324. (doi:10.1210/en.141.4.1317)
- Agic A, Xu H, Altgassen C, Noack F, Wolfler MM, Diedrich K, Friedrich M, Taylor RN & Hornung D. Relative expression of 1,25-dihydroxyvitamin D3 receptor, vitamin D 1α-hydroxylase, vitamin D 24-hydroxylase, and vitamin D 25-hydroxylase in endometriosis and gynecologic cancers. *Reproductive Sciences* 2007 14 486–497. (doi:10.1177/1933719107304565)
- Parikh G, Varadinova M, Suwandhi P, Araki T, Rosenwaks Z, Poretsky L & Seto-Young D. Vitamin D regulates steroidogenesis and insulin-like growth factor binding protein-1 (IGFBP-1) production in human ovarian cells. *Hormone and Metabolic Research* 2010 42 754–757. (doi:10.1055/s-0030-1262837)
- Johnson JA, Grande JP, Roche PC & Kumar R. Immunohisto-chemical detection and distribution of the 1,25-dihydroxy- vitamin D3 receptor in rat reproductive tissues. *Histochemistry and Cell Biology* 1996 105 7–15. (doi:10.1007/BF01450873) Merke J, Hügell U & Ritz E. Nuclear testicular 1,25-dihydroxy- vitamin D3 receptors in Sertoli cells and seminiferous tubules of adult rodents. *Biochemical and Biophysical Research Communications* 1985 127 303–309. (doi:10.1016/S0006-291X(85)80159-5)
- Blomberg Jensen M, Nielsen JE, Jørgensen A, Rajpert-De Meyts E, Kristensen DM, Jørgensen N, Skakkebaek NE, Juul A & Leffers H. Vitamin D receptor and vitamin D metabolizing enzymes are expressed in the human male reproductive tract. *Human Reproduction* 2010 25 1303–1311. (doi:10.1093/humrep/deq024)
- Lerchbaum, E., & Obermayer-Pietsch, B. (2012). Vitamin D and fertility: a systematic review. *European Journal of Endocrinology*, 166(5), 765-778.
- Muscogiuri, G., et al. (2014). Vitamin D and fertility: A systematic review and meta-analysis. *European Journal of Endocrinology*, 170(3), 377-387.
- Ozkan S, Jindal S, Greenseed K, Shu J, Zeitlian G, Hickmon C & Pal L. Replete vitamin D stores predict reproductive success following in vitro fertilization. *Fertility and Sterility* 2009 94 1314–1319. (doi:10.1016/j.fertnstert.2009.05.019)
- Anifandis GM, Dafopoulos K, Messini CI, Chalvatzas N, Liakos N, Pournaras S & Messinis IE. Prognostic value of follicular fluid 25-OH vitamin D and glucose levels in the IVF outcome. *Reproductive Biology and Endocrinology* 2010 8 91. (doi:10.1186/1477-7827-8-91)
- Rudick, B. J., et al. (2012). Effects of vitamin D deficiency on fertility and reproductive outcomes in women: An evidence-based review. *International Journal of Women's Health*, 4, 433–443.
- Yildizhan R, Kurdoglu M, Adali E, Kulusari A, Yildizhan B, Sahin HG & Kamaci M. Serum 25-hydroxyvitamin D concentrations in obese and non-obese women with polycystic ovary syndrome. *Archives of Gynecology and Obstetrics* 2009 280 559–563. (doi:10.1007/s00404-009-0958-7)
- Mahmoudi T, Gourabi H, Ashrafi M, Yazdi RS & Ezabadi Z. Calcitropic hormones, insulin resistance, and the polycystic ovary syndrome. *Fertility and Sterility* 2010 93 1208–1214. (doi:10.1016/j.fertnstert.2008.11.031)
- Wehr E, Moeller R, Horejsi R, Giuliani A, Kopera D, Schweighofer N, Groselj-Strele A, Pieber TR & Obermayer-Pietsch B. Subcutaneous adipose tissue topography and metabolic disturbances in polycystic ovary syndrome. *Wiener Klinische Wochenschrift* 2009 121 262–269. (doi:10.1007/s00508-009-1162-2)
- Wortsman J, Matsuoka LY, Chen TC, Lu Z & Holick MF. Decreased bioavailability of vitamin D in obesity. *American Journal of Clinical Nutrition* 2000 72 690–693.
- Compston JE, Vedi S, Ledger JE, Webb A, Gazet JC & Pilkington TR. Vitamin D status and bone histomorphometry in gross obesity. *American Journal of Clinical Nutrition* 1981 34 2359–2363
- Sathyapalan T, Shepherd J, Arnett C, Coady AM, Kilpatrick ES & Atkin SL. Atorvastatin increases 25-hydroxy vitamin D concentrations in patients with polycystic ovary syndrome. *Clinical Chemistry* 2010 56 1696–1700. (doi:10.1373/clinchem.2010.144014)
- Rashidi B, Haghollahi F, Shariat M & Zayerii F. The effects of calcium-vitamin D and metformin on polycystic ovary syndrome: a pilot study. *Taiwanese Journal of Obstetrics and Gynecology* 2009 48 142–147. (doi:10.1016/S1028-4559(09)60275-8)
- Hammoud, A. O., et al. (2012). Association of 25-hydroxyvitamin D levels with semen and hormonal parameters. *Asian Journal of Andrology*, 14(6), 855-859
- Blomberg Jensen M, Bjerrum PJ, Jessen TE, Nielsen JE,

- Joensen UN, Olesen IA, Petersen JH, Juul A, Dissing S & Jørgensen N. Vitamin D is positively associated with sperm motility and increases intracellular calcium in human spermatozoa. *Human Reproduction* 2011 26 1307–1317. (doi:10.1093/humrep/der059)
22. Holick MF, Binkley NC, Bischoff-Ferrari HA, Gordon CM, Hanley DA, Heaney RP, Murad MH & Weaver CM. Evaluation, treatment, and prevention of vitamin D deficiency: an endocrine society clinical practice guideline. *Journal of Clinical Endocrinology and Metabolism* 2011 96 1911–1930. (doi:10.1210/jc.2011-0385)
23. Heaney RP. Vitamin D in health and disease. *Clinical Journal of the American Society of Nephrology* 2008 3 1535–1541. (doi:10.2215/CJN.01160308)



**DR. J JANICE ALPHONSA SECOND YEAR OG PG
GUIDE: DR. PUNITHAVATHI M.S OG
DEPARTMENT OF OBSTETRICS AND GYNECOLOGY
DHANALAKSHMI SRINIVASAN MEDICAL COLLEGE AND HOSPITAL**

A CASE OF HYPEREMESIS GRAVIDARUM INDUCED HYPOKALEMIC PARALYSIS

Introduction:

Hyperemesis gravidarum is severe unrelenting nausea and vomiting that produces, weight loss, dehydration, ketosis, alkalosis from loss of hydrochloric acid and hypokalemia. Hypokalemia is one of the most prevalent disorders of fluid and electrolyte imbalance in clinical practice, but in obstetrics it amount to 1% of total pregnancies. Normal values of potassium in the blood lie between 3.5 and 5.5 meq/L. Definition of hypokalemia is a potassium level that is below 3.5 meq/L. clinically, hypokalemia might present with weakness of the muscles and, in certain cases, arrhythmias. Inadequate intake of potassium linked with increased potassium loss through the route of skin, gastrointestinal tract, or kidneys and increased consumption of potassium by cells as a result of increased cell production might result in hypokalemia.

Case Report:

An 18 year old G2P1L1 at 15 weeks+4 days came to opd with. H/o excessive vomiting for the past 2 months, generalized weakness in all 4 limbs and difficulty in using both the lower limbs. There was no history of fever, seizures, headache, giddiness, blurring of vision, diplopia, and diarrhea. On examination patient had power of 3/5 in both the lower limbs and 5/5 in upper limbs, ankle knee triceps and biceps reflex were absent. Plantar on right was mute and left was extensor. Patient had no cerebellar dysfunction. All routine investigation sent. Patient was found to have hypokalemia. Diagnosis of HYPOKALEMIC PARALYSIS DUE TO HYPEREMESIS GRAVIDARUM was made. Patient was started on INJ. KCL INFUSION 40MEQ IN 500 ML NS AT 10 MEQ/HR FOR 5 HOURS AT RATE OF 100ML/HR. After 5 hours of infusion serum potassium was reassessed and was found to be 3.8 meq/l. Patient had symptomatic improvement and power of lower limbs improved to 4/5 all the reflexes improved.

Discussion:

One of the most common causes of high-risk pregnancy is hyperemesis gravidarum. Hyperemesis gravidarum presents with persistent vomiting, which is not relieved despite the use of antiemetics . It can be attributed to the hypersecretion of beta-hCG . Prompt diagnosis of this condition is of utmost importance as it can not only be deleterious to fetal health but can also affect maternal health adversely. It can lead to not only electrolyte disturbances but can affect kidney function too. Hypokalemia is a condition in which there is depletion of serum potassium. A level of serum potassium less than 3.5 mg/dl can be defined as hypokalemia . Its manifestations include muscle weakness as well as cardiac complications such as QT prolongation, flattening of T wave, the appearance of U wave, and ST segment depression. Causes for hypokalemia can be attributed to low potassium intake, loss of potassium from various sources such as persistent diarrhea, and loose stools leading to total depletion of body potassium and serum potassium. Persistent vomiting in hyperemesis gravidarum can cause severe hypokalemia . Hypokalemia leading to muscle paralysis is a common occurrence. But hypokalemia paralysis occurs infrequently during pregnancy. Acute muscle weakness occurs in conjunction with low potassium levels. Any pregnancy that is linked to paralysis is considered high risk and should be treated as such. If a woman is experiencing major weakness or paralysis attacks, the related cardiac, respiratory, and muscular disorders may represent a risk, and she will need to be closely monitored and given informed treatment. A comprehensive cardiovascular examination is required. If an episode of weakness or paralysis occurs during labor and delivery, the medical team must be prepared to address it appropriately. Quadriplegia is a rare complication that must be distinguished from Guillain-Barré syndrome, transverse myelitis, and

spinal cord compression. Some patients may endure recurrent episodes of weakness in between attacks, although they will generally recover completely. The main steps in the management include exclusion of other causes of hypokalemia, potassium replacement, hydration and close monitoring of the cardiac rhythm and serum potassium levels. The underlying cause must be searched for to prevent the persistence or recurrence of paralysis. Acetazolamide, dichlorphenamide, or potassium-sparing diuretics decrease attack frequency and severity on chronic basis but not acutely.

Conclusion:

Hypokalemia caused by hyperemesis is rare complication in pregnancy which can be treated easily if diagnosed at early stage. If left untreated it can be a life-threatening condition; hence, early diagnosis and prompt treatment are of dire need. More research needs to be directed into this entity as it will educate the treating physicians and obstetricians and thus help in reducing maternal mortality.

REFERENCES:

1. Dr. Archana Gupta, MD, Dr. Gaurav kavi, MD, Dr. Neelima Singh, MD, Dr. Sankalp Dwivedi, MBBS , Hyperemesis Induced Acute Quadripareisis In Pregnancy - A Case Report, IOSR Journal of Dental and Medical Sciences (IOSR-JDMS) e-ISSN: 2279-0853, p-ISSN: 2279-0861. Volume 5, Issue 4 (Mar.- Apr. 2013), PP 62-63
2. Srinivas Naik , Dhruv Talwar , Sourya Acharya , Sunil Kumar , Deepti Shrivastava,Hyperemesis Gravidarum Presenting as Severe Hypokalemic Periodic Paralysis and Type II Respiratory Failure: A Different Form of Thyroid Storm? DOI: 10.7759/cureus.19566.
3. F.Gary Cunningham Kenneth J.Leveno Jodi S. Dashe Barbara L Hoffman Catherine Y,Spong Brian M. Casey, Williams Obstetrics 26th edition.



**DR.KEERTHANA S SECOND YEAR POST GRADUATE
GUIDE :DR.PUNITHAVATHI M.S OG (ASSOCIATE PROFESSOR)
DEPARTMENT OF OBSTETRICS AND GYNECOLOGY
DHANALAKSHMI SRINIVASAN MEDICAL COLLEGE AND HOSPITAL**



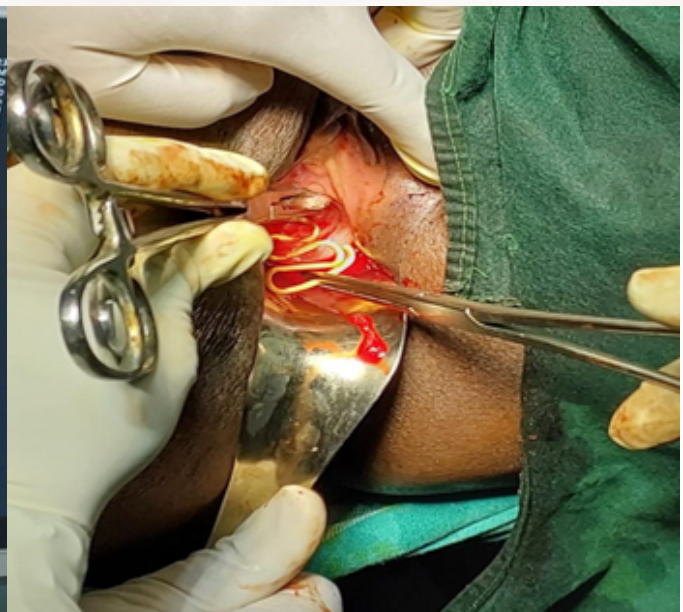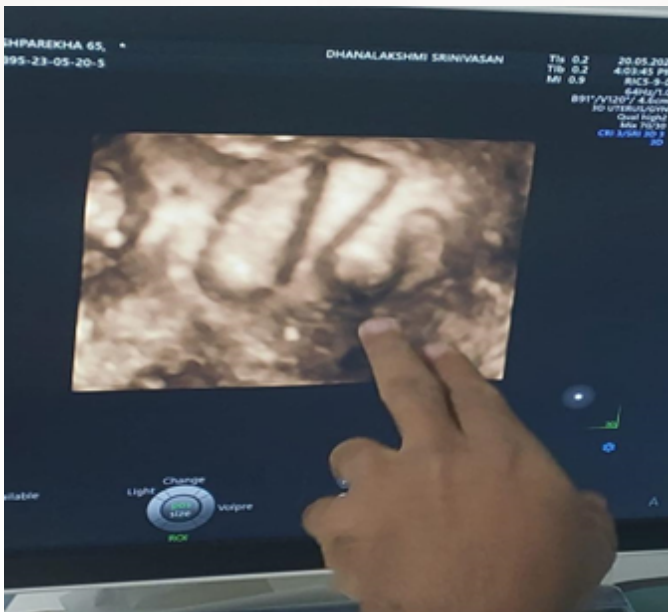**A CASE OF FORGOTTEN LIPPES LOOP OR IUCD IN
POST MENOPAUSAL WOMEN LEADING TO POST
MENOPAUSAL BLEEDING AND PYOMETRA**

INTRODUCTION:

Intrauterine contraceptive devices are a widely used method of contraception. Its cheap, easy and an effective method. The first intrauterine device was lippes loop which was double S shaped trapezoid loop introduced in 1962. Nowadays third generation intrauterine devices are used which are effective for 5 and as well as 10 years Here we presented rare case, of retained lippes loop in an 62 year old who presented with post menopausal bleeding, foul smelling discharge pv It's a rare incidence supported by clinical and MRI. Removal of retained IUCD'S and pyometra drainage done.

CASE REPORT

A 62 year old lady, P3L2/ Previous NVD/ Sterilized, post menopausal for 15 years, presented to gynec opd with c/o lower abdominal pain of two years duration and complaints of vaginal discharge which was blood mixed, foul smelling since two months. When asked about contraceptive history, she reported to undergone sterilization 30 years before with H/O IUCD removal done prior to surgery. There was no other surgical history Patient is k\c\o diabetes mellitus, hypertension under treatment since 7 years, and h/o recovery from stroke 3 years before. No other medical problem. On examination general condition was average, sterilization scar was visible on per abdomen





examination. Cervix was seen flushed with vagina, there was no growth There was also slight blood mixed discharge present at the time of examination. Pap smear was taken which was negative for intraepithelial lesion or malignancy with atrophic features. AN ULTRASOUND DONE DIAGNOSED AN RETAINED INTRAUTERINE LIPPES LOOP. She was advised admission with the impression of retained IUD and pyometra and given injectable antibiotic. Lippes loop removal was done under hysteroscopic guidance and endometrial curettage done with pyometrial drainage under intravenous sedation. On HPE of endometrial tissue and endocervical curettage, few fragmented tissues were seen showing endometrial glands and stroma. No dysplasia or malignancy was seen. The patient was discharged on third post operative day. On follow up she reported to have resolved her symptoms.

DISCUSSION: Removal of any misplaced or forgotten intrauterine device needs to be done. A forgotten IUCD can cause problems like infertility to postmenopausal bleeding, pain abdomen, fever. Complications can occur like ectopic pregnancy, hydrometra, pyometra and uterine perforation, bowel obstruction following perforation, infections and rarely death. There was no established evidence that intrauterine device retained after menopause can cause cancer but such retention of intrauterine device did confuse the diagnosis of post menopausal bleeding. The faculty of sexual and reproductive health care (FRSH) guidance on contraception for women aged 40 years stated that pyometra and actinomycosis have been reported in post menopausal women with retained IUCD and caused serious morbidity. Hence IUCD needed to be removed rather than left in situ.

According to WHO recommendations, removal of a misplaced IUCD must be done immediately after diagnosis was made.

CONCLUSION

Case reports are useful source of evidence where no evidence exists. Reporting of the rare case particularly rare complications, serious or otherwise associated with prolonged contraceptive use should be widely encouraged. After the detailed analysis, I am of the opinion that we are not justified in leaving an IUD even if inert and asymptomatic, as complications cannot be predicted and can develop at any stage. Complications are often severe and unusual nature which can result in high level of morbidity to the patient and many a times have life threatening implications.

REFERENCE

1. Faculty of sexual and reproductive health care clinical effectiveness unit. Enquiry reference. 11 Dec 2012:3941. [Google Scholar]
2. Lippes J, Zielesny M. Analysis of Intrauterine contraception. Amsterdam: North Holland; 1975. The loop after 10 years. In: Hefnawi F, Segal SJ, eds; pp. 417-28. [Google Scholar]
3. Vessey MP, Yeates D, Flavel R, McPherson K. Pelvic inflammatory disease & the intrauterine contraceptive device: findings in large cohort study. Br Med J. 1981; 282: 855-57 [PubMed] [Google Scholar]



**DR. B.C. SAMYUKTHA, FIRST YEAR OG PG
GUIDE – DR. PUNITHAVATHI M.S OG
DEPARTMENT OF OBSTETRICS AND GYNECOLOGY ,
DHANALAKSHMI SRINIVASAN MEDICAL COLLEGE AND HOSPITAL**

A RARE CASE OF ADENOSARCOMA – HISTOLOGICAL SURPRISE

CASE REPORT:

49 Years old, P1L1, NVD sterilized came with c/o heavy menstrual bleeding for 2 months, associated with clots, pain and foul smelling discharge. Changes 5-6 pads per day. C/o lower abdominal pain for 1 week. No h/o intermenstrual bleeding, no c/o burning micturation, no h/o white discharge, no h/o breathing difficulty/palpitation, no h/o mass descending PV. Not a known case of DM/SHTN/BA.

On examination patient's vitals stable

Per abdomen: uterus 14 weeks size, ST scar+.

Per speculum: foul smelling discharge with necrosed mass coming through cervix, vagina healthy.

Per vaginal: friable mass of 4*3cm coming out though the cervix, specimen sent for HPE. Doesn't bleed on touch cervix is lateralized to right side. Uterus 14 -16 weeks size, mobile, non tender, foul smelling discharge +.

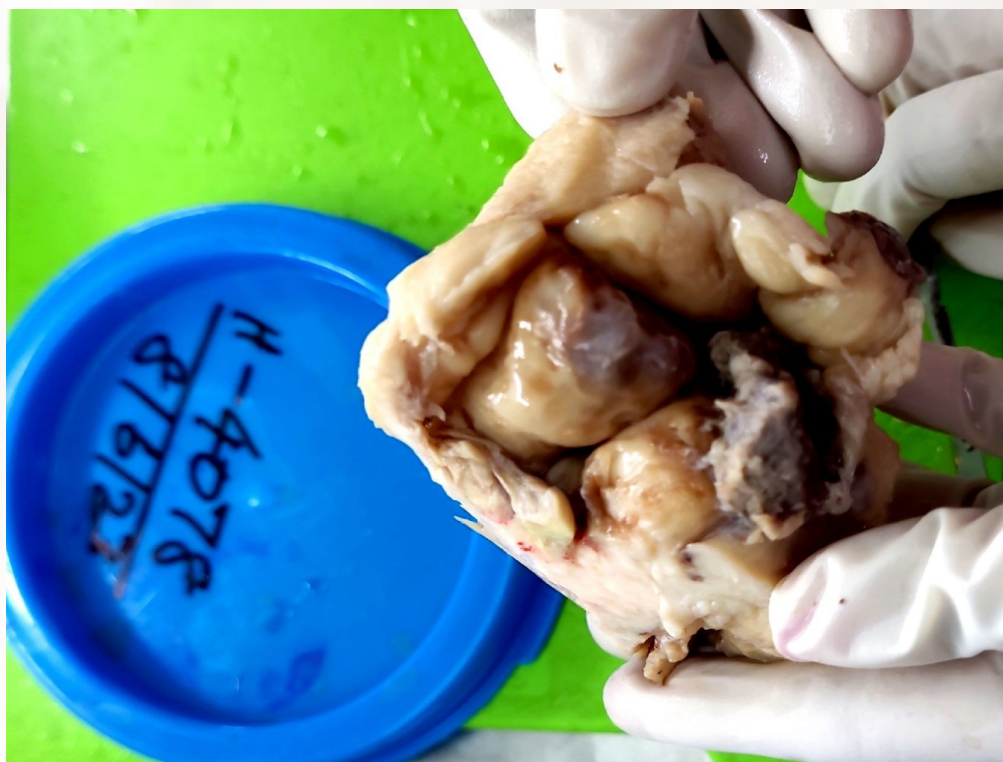USG Abomen and Pelvis: bulky uterus, well defined large pedunculated submucosal fibroid polyp of size 13*4cm arising from the fundus and descending the uterine cavity and cervical canal.

All other routine investigations done. Patient was optimized for surgery. Patient was planned for LAVH.

Surgical specimen was sent for histopathological examination. Post op period uneventful, patient was discharged. HPE revealed a histological surprise – ADENOSARCOMA, LOW GRADE, PT1PNX.

DISCUSSION:

In 1974, Clement and Scully reported a series of tumours of female genital tract described as "mixed tumours of uterus, in which the stromal component



has been malignant, but the epithelial elements, benign" and named these adenosarcoma.

Mullerian adenosarcoma is an uncommon biphasic tumour composed of malignant stromal and benign

epithelial components. Morphologically, it has a broad leaflike architecture, similar to phyllodes tumour of breast.

The mesenchymal component is typically a low grade spindle cell sarcoma, whereas the epithelial counterpart is endometrioid with frequent squamous or mucinous metaplasia and may show mild to moderate atypia.

They are rare and account for approx 3% of all uterine cancers.

Although uncommon adenosarcoma affects women of a broad age range. The incidence is highest in perimenopausal or postmenopausal women, but cases have been reported in children as young as 10 years. Patients may present clinically with abnormal vaginal bleeding and/or pelvic pain, or in a large percentage of cases, with no symptoms. The symptoms may mimic fibroid, like enlarged uterus, AUB, and tissue protruding the internal os.

Although the uterine corpus is by far the most common primary site, adenosarcoma may also arise in the cervix, ovary, fallopian tube or vagina. Adenosarcoma occurring outside the female genital tract represents tumours arising from preexisting endometriosis. Some studies suggest that the use of tamoxifen may have a role in the pathogenesis of adenosarcoma.

Investigation of choice of adenosarcoma is MRI.

The immunohistochemical markers for adenosarcoma are CD10 and Wt1.

The FIGO staging system for uterine adenosarcoma

- Tumour limited to uterus
- IA Tumour limited to endometrium/endocervix with no myometrial invasion
 - IB < 50% myometrial invasion
 - IC > 50% myometrial invasion
- Tumour extends beyond the uterus, within the pelvis
 - IIA Adnexal involvement
 - IIB Involvement of other pelvic tissues
- III Tumour invades abdominal tissues (not just protruding into the abdomen)
 - IIIA One site

- IIIB > 1 site
- IIIC Metastasis to pelvic and/or para-aortic lymph nodes
- IV
 - IVA Tumour invades bladder and/or rectum
 - IVB Distant metastasis

TREATMENT

Grade IA – without myometrial invasion or sarcomatous overgrowth – offer hysterectomy with BSO.

>/= Grade IB - with myometrial invasion or sarcomatous overgrowth – hysterectomy with BSO + LND

If patient is not willing for hysterectomy, hysteroscopic local excision of lesion with follow up.

Follow up – 0-2 years – USG once in 3 months.

Post op – 2-5 years – USG once in 6 months.

>5 years – USG yearly once.

It is important to assess for the presence of sarcomatous overgrowth and myometrial invasion, which are the prognostic factors. The 2 year progression free and overall survival rates for tumours with sarcomatous overgrowth were 20% compared with 100% for adenosarcoma lacking sarcomatous overgrowth. Tumours that arise in the ovary or extrauterine sites tend to have a higher recurrence rate secondary to lack of a physical barrier to spread within the pelvis and abdomen.

CONCLUSION –

Our patient was a case of adenosarcoma masked as a fibroid. Since the pathological primary tumour was stage 1 with no nodal involvement and no metastasis, she had a good prognosis. She was discharged and advised to review after 6 months.

Best Compliments From

In PCOS*

NORMOZ

Myo-inositol, D-Chiro-inositol, Chromium and Vitamin D tablets

Right Ratio (40:1) for Quicker Action in PCOS

For Oral Contraception



Freedase 30

Dienogest 2 mg + Ethinyl estradiol 0.03 mg

Benefits Beyond Pregnancy Free Days

From Pre-conception to Lactation*



DESIGNED TO DELIVER HIGH STANDARD NUTRITION



Inca Life Sciences

a SUN PHARMA division



Neonatal Care Center & NICU

Velan Hospitals' Neonatal Care Center & NICU provides specialised care for newborn infants, requiring intensive monitoring and treatment. Our Neonatologists, Paediatricians, nurses, and healthcare professionals are committed to delivering unparalleled treatment for babies and mothers.



German Modular NICU by KLS Martin – Neonatal Care units by Dräger – for the first time in Trichy

Our Expertise

- NNF-accredited unit
- Exclusive NICU unit
- 24/7 availability of Neonatologists & Pediatricians

Our Facilities

- CT Brain facility
- Neurosonogram
- Continuous EEG monitoring
- Baby Log 8000 Plus Dräger Ventilator
- Ventilators for Neonatal and new-born babies
- Double Surface Phototherapy units with feeding rooms for mothers
- Radiant Heat Warmer with Dual Sensor

Conditions We Treat

- Perinatal asphyxia
- Neonatal jaundice
- Neonatal respiratory distress
- Refractory neonatal seizures
- Inborn error of metabolism workup

Our Services

- Postnatal followup
- Developmental screening
- Transcutaneous bilirubin meter for non-invasive bilirubin estimation
- NICU-trained nurses for special care to preterm and low birth weight babies
- Immunization services and counselling
- Lactation consultation by Pediatricians



Velan Speciality Hospitals Pvt. Ltd.

0431 2334444 | www.velanhospitals.com

No.1, Highways Colony, Subramaniyapuram, Jail Corner, Pudukottai Main Road, Trichy, Tamilnadu - 620020.





**DR.PRITIKA FIRST YEAR OG PG,
GUIDE: DR.J.PUNITHAVATHI MS OG,
DEPARTMENT OF OBSTETRICS AND GYNECOLOGY
DHANALAKSHMI SRINIVASAN MEDICAL COLLEGE AND HOSPITAL.**

DIAGNOSTIC DILEMMA AT TERM-ADNEXAL MASS DURING C SECTION

INTRODUCTION

- Adnexal mass during pregnancy is usually an incidental finding due to wide spread use of USG routinely
- Literature says this occurs 1 in 76 pregnancy
- Most of them are Functional cysts like corpus luteal and follicular cysts which are hormone dependent and regress spontaneously by 20weeks. Other Benign lesions include Teratoma, Serous and Mucinous cystadenoma and Endometrioma
- Malignant lesions include Germ cell tumors, Stromal cell tumors and Borderline tumors.
- Most of them are asymptomatic and symptoms depends on the size, location and compression of adjacent structures.

CASE REPORT

Clinical presentation

A 25y old female, A case of G4P2L2A1 at 35 weeks +2days of GA , Previous 1 LSCS ,Previous Laprotomy 3 years ago in view of mucinous cystadenoma , came to Labour room with complaints of pain abdomen x 2days .She was able to perceive fetal movements well and there was no H/O draining ,bleeding p/v, fever or URTI. She was admitted for futher evaluation

Examination

On examination: BP-120/100mmhg, PR-102bpm, RR-18/m, Temperature-Afebrile

NST showed Fetal Tachycardia , P/A- Uterus 32 -36

weeks size, Irritable, Cephalic, FHS +,SPT Scar+ ,Scar tenderness+

P/V -Cervix soft, Posterior, Uneffaced, os closed, No show or draining p/v

Investigations

On her 1st visit at 6weeks of gestational age ,on routine USG it was found that she had a simple cyst measuring 3.2x3.3cm in the right ovary

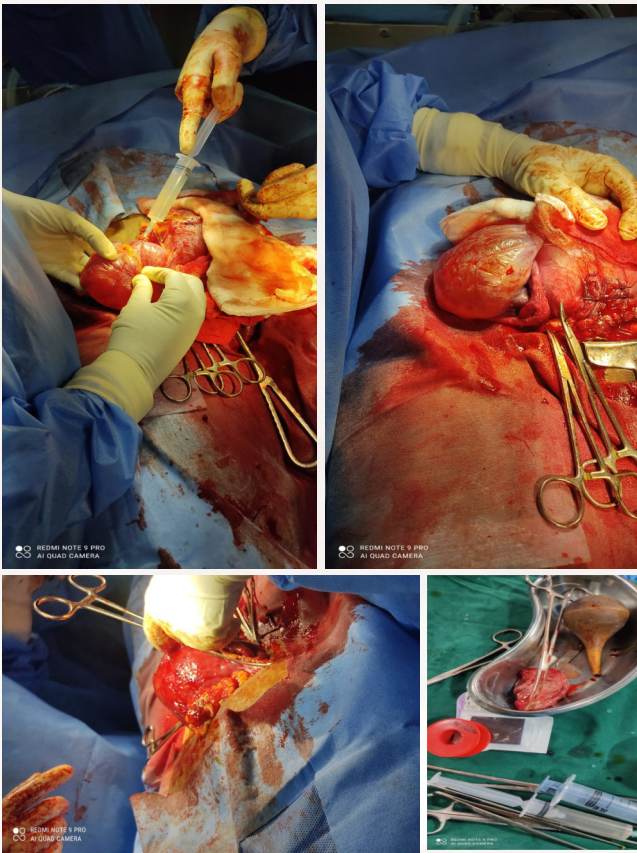
During her subsequent scans upto 12 weeks the cyst remained same size and she had no symptoms or signs.

Management

- In view of Maternal and Fetal Tacycardia , ? Scar dehiscence she was taken up for Emergency Repeat LSCS

Intra operative findings:

- Lower uterine segment was not formed well and was vascular.
- Cephalic presentation
- Liquor was clear and adequate
- Placenta and membranes - Anterior and removed completely
- Left side tube not visualised - H/O Previous Ovariectomy with Left Salphingectomy.
- Right side -Ovarian clear cyst of 8x8 cm adhered to the right lateral uterine wall and posterior wall of the uterus along with omental adhesions
- No PPH/Lateral extension.



Type of mass	Sonographic features
1. Functional cyst	
• Corpus luteum	Widespread appearance; 'Ring of fire' with Doppler.
• Follicular cyst	Mainly simple cyst < 10 cm, sometimes with debris.
• Haemorrhagic cyst	Fine interdigitating lines (fishnet); solid compounds with concave outer lining. No flow with Doppler.
2. Dermoid cyst	<ul style="list-style-type: none"> • Rokitansky nodule; a hyperechoic nodule with acoustic shadowing in a background of low-level echoes. • 'Tip of the iceberg' phenomenon, where a highly echogenic cyst, contents of sebum and hair, causes posterior attenuation of sound. • 'Dermoid mesh', multiple interdigitating lines and dots which are seen when hair is floating in sebum.
3. Serous cystadenoma	<ul style="list-style-type: none"> • Large simple cyst > 5 cm. • Thin septations or papillary formations.
4. Mucinous cystadenoma	<ul style="list-style-type: none"> • > 5 cm in diameter. • Multiple septae. • Heterogenic aspect.
5. Endometrioma	<ul style="list-style-type: none"> • Round thick regular wall; diffuse homogenous low-level internal echoes (chocolate cyst). Calcifications with acoustic shadowing • Not attached to the ovary.
6. Leiomyomas	<ul style="list-style-type: none"> • Round regular wall. • When outgrowing the blood supply central necrosis may be seen
7. Paraovarian cyst	<ul style="list-style-type: none"> • 1-2 cm simple cysts. • – Not attached to the ovary.

DISCUSSION

- Adenexal mass is pregnancy accounts for about 0.05-2.4%
- Due to widespread use of USG now a days the incidence is been increasing.
- Prompt diagnosis and appropriate treatment is essential to prevent complications.

Complications:

- Hemorrhage
- Rupture
- Torsion, Ischemia, Necrosis
- Need for emergency surgery
- Labour obstruction
- Progression to malignancy.

Benign adnexal masses discovered during early pregnancy sonography with their morphologic appearance on ultrasound:

Pregnancy-associated changes of ovarian masses

During pregnancy the same ovarian masses can be found as those diagnosed in the non-pregnant population. In addition, a number of pregnancy-associated masses may occur. When a pregnant patient presents with a symptomatic adnexal mass early in pregnancy, an ectopic pregnancy must always be ruled out since an undiagnosed ectopic pregnancy may have a potentially lethal outcome. Other pregnancy-associated masses are benign and typically present as bilateral cysts, except for luteomas who present as unilocular solid masses. The most common pregnancy-associated ovarian masses are functional cysts like the corpus luteum of pregnancy and theca-lutein cysts. Most of these cysts will resolve after the first 14-16 weeks of gestation but some, like the theca lutein cysts, can persist until after delivery. Masses still present after 16 weeks of gestation are predominantly non-functional. Endometriomas can have a strongly changed appearance during pregnancy because of decidualized walls due to high levels of progesterone in pregnancy. A previous history of symptoms of endometriosis can be indicative. However, when the diagnosis remains uncertain further investigation is advised to rule out a malignant neoplasm

Diagnosis:

1. **Ultrasound**
2. **The IOTA (International Ovarian Tumor Analysis)**

IOTA simple rules:

For predicting a malignant tumor (M features)
M1 – Irregular solid tumor
M2 – Presence of ascites
M3 – At least four papillary structures
M4 – Irregular multilocular solid tumor with largest diameter
M5 – Very strong blood flow (colour score 4)
For predicting a benign tumor (B features)
B1 – Unilocular
B2 – Presence of solid components, of which largest solid component has largest diameter < 7 mm
B3 – Presence of acoustic shadows
B4 – Smooth multilocular tumor with largest diameter < 100 mm
B5 – No blood flow (colour score 1)

Rule 1: If one or more M features are present in absence of B feature, mass is classified as malignant.

Rule 2: If one or more B features are present in absence of M feature, mass is classified as benign.

Rule 3: If both M features and B features are present, or if no B or M features are present, result is inconclusive and second stage test is recommended.

MRI

Tumour markers

During pregnancy elevations of tumour markers are mostly associated with the normal physiologic changes of pregnancy and presence of obstetric complications (miscarriage, preeclampsia, HELLP). When an ovarian mass is diagnosed in pregnancy, CA-125 levels may help to distinguish between a benign or malign lesion and can be used to evaluate treatment. However, decidua- and amnion cells also produce CA-125 resulting in higher CA-125 levels during pregnancy especially in the first and third trimester (respectively because of trophoblast invasion and detachment of the placenta). Tumour markers associated with germ cell tumours (e.g. AFP and b-hCG) and granulosa cell-tumours (Inhibin B and AMH) can also be elevated in normal pregnancy and can therefore only be used as follow-up.

HPE Reports showed

1. Benign ovarian lesion 25%
2. Malignant 12.5%
3. Borderline 6.3%
4. Adenocarcinoma 3.1%

Treatment:

- Laprotomy > Laparoscopy, Robotic and Open surgery
- To be operated if the size >6cm, growth >0.35cm per week, to be taken up for surgery in 2nd trimester or during c-section or 6 weeks later the delivery.

CONCLUSION

Our patient was asymptomatic and did not have any complications until 35 weeks of gestational age because of the cyst. And the cyst was found as an incidental finding during C-Section when the patient



presented with abdominal pain

- This case is of interest due to its rare entity and its potential to mimic ovarian cancer both clinically and radiologically.
- Hence it is utmost important to recognize adnexal mass of ovarian origin and distinguish from non-ovarian ones and exclude malignancy.

☒ Incidental mass to be extirpated in order to exclude the possibility of malignancy and avoid additional surgery following C-Section

Ovarian cysts or masses during pregnancy should be accurately evaluated to decide the most appropriate treatment option. Ultrasound and MRI are safe and allow distinguishing between benign and malignant lesions. A wait-and-see strategy is advised for an ovarian cyst with benign features. Masses with septa, solid components, papillae or nodules, or when persisting after 16 weeks of pregnancy should be further investigated. Treatment options including surgical procedures should be discussed for each patient individually. Both open surgery and laparoscopy can be performed considering the tumour diameter, gestational age and surgical expertise. When advanced stage invasive ovarian cancer is diagnosed, termination of pregnancy may be considered in early pregnancy, otherwise chemotherapy can be administered during second and third trimester. When there is high suspicion of malignancy, a multidisciplinary approach is necessary, and preferably patients should be referred to centres with specialized experience.

REFERENCE

1. Yacobozzi M, Nguyen D, Rakita D. Adnexal masses in pregnancy. *Semin Ultrasound CT MR.* 2012;33:55–64. [PubMed] [Google Scholar]
2. Leiserowitz GS. Managing ovarian masses during pregnancy. *Obstet Gynecol Surv.* 2006;61:463–70. [PubMed] [Google Scholar]
3. Glanc P, Salem S, Farine D. Adnexal masses in the pregnant patient: A diagnostic and management challenge. *Ultrasound Q.* 2008;24:225–40. [PubMed] [Google Scholar]
4. Giuntoli RL, 2nd, Vang RS, Bristow RE. Evaluation and management of adnexal masses during pregnancy. *Clin Obstet Gynecol.* 2006;49:492–505. [PubMed] [Google Scholar]
5. Hoover K, Jenkins TR. Evaluation and management of adnexal mass in pregnancy. *Am J Obstet Gynecol.* 2011;205:97–102. [PubMed] [Google Scholar]
6. Aggarwal P, Kehoe S. Ovarian tumours in pregnancy: A literature review. *Eur J Obstet Gynecol Reprod Biol.* 2011;155:119–24. [PubMed] [Google Scholar]
7. Munnell EW. Primary ovarian cancer associated with pregnancy. *Clin Obstet Gynecol.* 1963;30:983–93. [PubMed] [Google Scholar]
8. Graham L. ACOG releases guidelines on management of adnexal masses. *Am Fam Physician.* 2008;77:1320–3.



**DR.S E SWETHA FIRST YEAR OG PG
GUIDE: DR.J.PUNITHAVATHI MS,OG.
DEPARTMENT OF OBSTETRICS AND GYNECOLOGY
DHANALAKSHMI SRINIVASAN MEDICAL COLLEGE AND HOSPITAL**

A CASE OF UNICORNUATE UTERUS WITH UNILATERAL ABSENT OVARIES

INTRODUCTION:

Congenital anomalies are more common in subfertile patients than in fertile women. Prevalance of congenital uterine anomalies varies between 2.4-5%. Congenital malformation of mullarian system are probably caused by multifactorial, polygenic and familial factors. Of all mullarian defects unicornuate uterus is found in 3-13% of women. However the prevalence of unicornuate uterus accounts for about 0.3% of whole population, 0.6% in infertile population, 0.2 % in fertile population. Mullarian system anomalies coexists with ectopic or undescended ovaries. However our case reports about unicornuate uterus with absent unilateral ovary and tubes with hypertrophied broad ligament on same side.

CASE REPORT:

A 45 yr old P3L3A2 presented to hospital with chief complaints heavy menstrual bleeding occurring once in 15 days lasting for 4 days associated with severe dysmenorrhea. Patient was on Norethisterone tablets on and off for over a period of 6 months. Patient presented to DSMCH for surgical management as despite medical management her symptoms persisted.

Patient's obstetrics history revealed first 2 spontaneous abortion @ 5months of gestational age and 6 months of gestational age respectively. Other 3 deliveries are preterm @ home. Patient has no history of any previous surgery.

Investigations done were found to be within normal limits. USG report shows anteverted uterus of 10*8*6cm size, with heterogenous echogenicity with

thickened junctional zone and few subendometrial hyperechoic striations suggestive of diffuse uterine adenomyosis, ET-3.4mm. PAP smear done revealed negative for intraepithelial lesion/malignancy. Patient posted for LAVH where intraoperative findings were found to be :

- Uterus of 12 wks size
- Myohyperplasia+
- Left side tubes and ovaries normal.
- Right side round ligament hypertrophied , ovaries and tubes absent.

Intraoperative and postoperative period uneventful.

Coexistence of unicornuate uterus with absent unilateral ovary and tubes on same side is a rare finding in a fertile women which was incidentally found in a case admitted for LAVH.

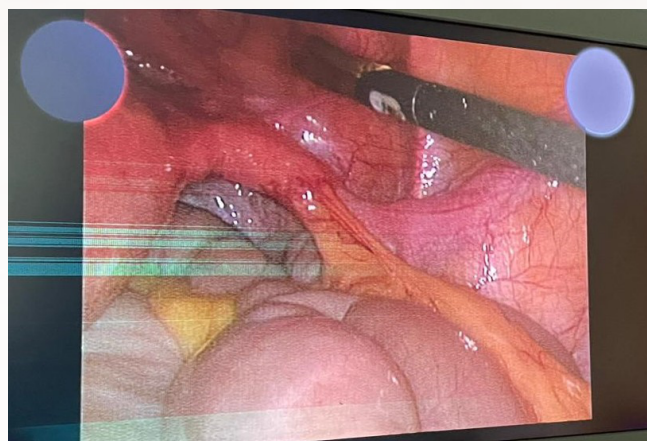


FIG :1 HYPERTROPHIED RIGHT BROAD LIGAMENT WITH ABSENT TUBES AND OVARY.

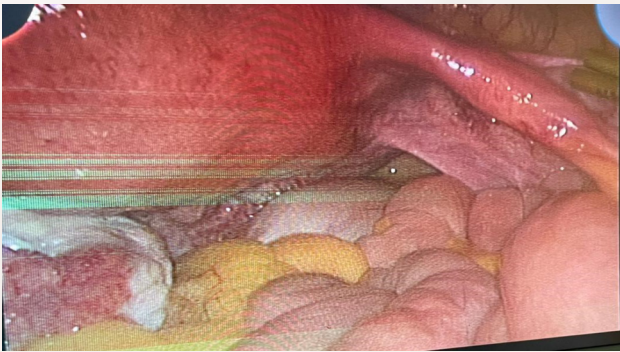

FIG:2 HYPERTROPHIED RIGHT BROAD LIGAMENT WITH ABSENT TUBES AND OVARY WITH OVARY ON RIGHT SIDE

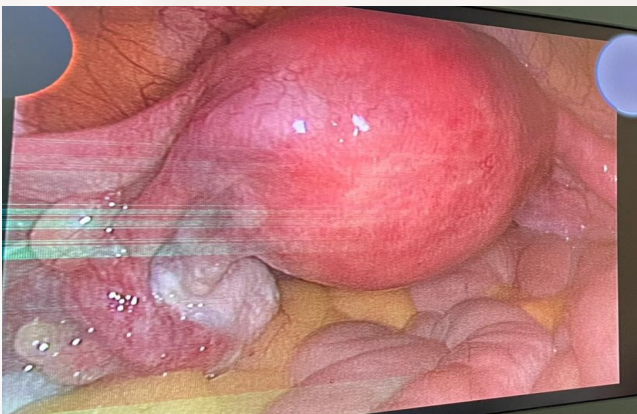

FIG:3 UNICORNUATE UTERUS WITH ABSENT RIGHT TUBE AND OVARY WITH HYPERTROPHIED RIGHT ROUND LIGAMENT

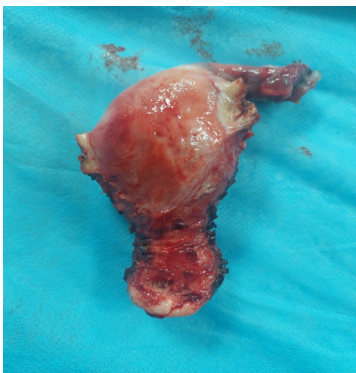

FIG:4 UNICORNUATE UTERUS WITH LEFT TUBE DISCUSSION:

UNICORNUATE UTERUS:

Uterine malformation results from abnormal development of MULLARIAN DUCT during embryogenesis. Unicornuate uterus in which partial or

complete loss of one mullarian duct . A unicornuate uterus has single cervix and vagina and commonly associated with renal and skeletal anomalies. Unicornuate uterus is commonly associated with rudimentary horn either communicating or non communicating with the cavity

Diagnosis of unicornuate uterus is made out by transvaginal ultrasound, 3D usg, sonohysterography, MRI, and hysteroscopy.

Patient with unicornuate uterus may need special attention during pregnancy as miscarriage , fetal demise, premature birth and malpresentation are more common.

ABSENT OVARIES:

Ovaries develop from genital ridge which are thickening of mesothelial layer of peritoneum. The ovary differentiates into central part , the medulla covered by a surface layer , the germinal epithelium. Germ cells originate from dorsal endoderm of yolk sac. They migrate to gonadal ridge hence called oogonia

In our case unicornuate uterus with absent ovary and tubes with hypertrophied round ligament found. As the patient has completed family and LAVH done in view of diffuse adenomyosis with failed medical management.

CONCLUSION

Uterine malformations are of prime consideration in case of infertility where correction surgeries along with closely monitored antenatal period required. Some cases it is an incidental finding where the female is asymptomatic fertile.

REFERENCE

- Acien P, Acien M. Diagnostic imaging and cataloguing of female genital malformations, insights. *Imaging*. 2016;7(5):713–726. doi: 10.1007/s13244-016-0515-4. (2016) -DOI-PMC-PubMed
- Gomez-Lobo V. In: *Williams Gynecology*. 4e. Hoffman B.L., Schorge J.O., Halvorson L.M., Hamid C.A., Corton M.M., Schaffer J.I., editors. McGraw-Hill; 2020. Anatomic disorders. <https://accessmedicine.mhmedical.com/content.aspx?bookid=2658§ionid=...> (accessed March 31, 2021)
- Bhandari A., Mandal S. A case of dorsal agenesis of pancreas associated with unilateral renal agenesis, unicornuate uterus, and ovarian ectopia: a brief review and learning points. *Indian J. Radiol. Imaging*. 2020;30(3):395–399. doi: 10.4103/ijri.IJRI_165_19. -



PRESENTER : DR. K. SHOBAPRIYA 1YR MS OG PG
GUIDE : DR PUNITHAVATHY MS OG
 DEPARTMENT OF OBG ,DSMCH,PERAMBALUR

ARNOLD CHIARI MALFORMATION – A CASE REPORT

INTRODUCTION

Arnold-Chiari, or simply Chiari malformation, is the name given to a group of deformities of the posterior fossa and hindbrain (cerebellum, pons, and medulla oblongata). Issues range from cerebellar tonsillar herniation through the foramen magnum to the absence of the cerebellum with or without other associated intracranial or extracranial defects such as hydrocephalus, syrinx, encephalocele, or spinal dysraphism.

Classification

Chiari malformations are classified based on their morphology and severity of anatomic defects, typically through imaging (or autopsy).

Chiari I is the least severe and often found incidentally. It is characterized by one or both pointed (not rounded) cerebellar tonsils that project 5 mm below the foramen magnum, measured by a line drawn from the basion to the opisthion (McRae Line).

Chiari II consists of brainstem herniation and a towering cerebellum in addition to the herniated cerebellar tonsils and vermis due to an open distal spinal dysraphism/myelomeningocele.

Chiari III involves herniation of the hindbrain (cerebellum with or without the brainstem) into a low occipital or high cervical meningoencephalocele.

Chiari IV is now considered obsolete. Prior to becoming an obsolete diagnosis, it was already a more controversial and rare variant that demonstrated severe cerebellar hypoplasia, similar to primary

cerebellar agenesis. Previously some stated that myelomeningocele could be present, while others argued that the presence of myelomeningocele should then be classified as a Chiari II with a vanishing cerebellum.

Chiari V the most severe variant, represents cerebellar agenesis with occipital lobe descent and herniation through the foramen magnum

CASE REPORT

A 28YRS old PRIM1 with 20wks +3days booked & immunized at nearby phc at 14 wks + 5days first visit to DSMCH has come to opd for regular AN check up.

No h/o intake of pre and post conceptional folic acid and NT scan was not done

Anomaly scan done shows SLIUG 20+2D S/O OPEN SPINAL DEFECT WITH ARNOLD CHIARI MALFORMATION TYPE 2 WITH MENINGOCELE IN LUMBOSACRAL REGION

After explained about prognosis and long term complications of anomaly to patient

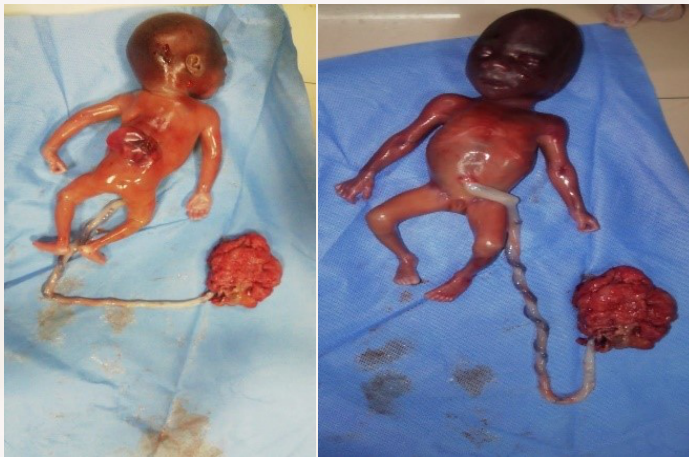PLANNED FOR MTP

Course in the hospital

She was admitted and ANC profile was done. She was taken up for MTP with T.MIFEPRISTONE AND T.MISOPROSTOL given at regular intervals and

Spontaneous expulsion of dead born fetus and placenta.

Fetus examination - A defect of size 2*2cm noted along the lumbosacral region



No other external anomaly noted

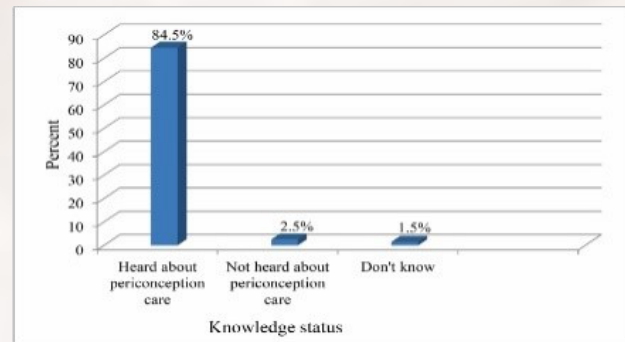
Weight of placenta -46g

Weight of fetus -300g

Length of cord -30cm

Hence discharged with advice of planning conception after 3 months with preconceptional folic acid

During pregnancy, a person needs Folic acid than usual because folic acid also helps the fetus grow and develop. One of its most important roles is preventing neural tube defects including spina bifida and anencephaly.



IMPORTANCE OF PRENATAL DIAGNOSIS

Diagnosis of chromosomal abnormalities in fetus is one of the most important challenges in modern perinatology. The most common chromosomal abnormalities in newborns are trisomies 21, 18, 13, monosomy X and other sex chromosome aneuploidies. Methods of prenatal diagnosis can be divided into **non-invasive and invasive techniques.**



Non-invasive methods include ultrasound and biochemical screening from maternal blood. Maternal serum screening in the second trimester has now been available for over two decades. More recently, first trimester screening tests offer women the opportunity of early screening for fetal aneuploidy

and the option of earlier diagnosis.

Invasive testing is advised for pregnancies that bear a high risk of being affected by a chromosomal aberration from family and individual history.

DISCUSSION

IMPORTANCE OF PRE AND POST CONCEPTION FOLIC ACID

Folic acid is a synthetic (human-made) form of folate. Folate is a type of B vitamin.

Everyone needs folate, but it is especially important during pregnancy because of its role in preventing birth abnormalities.

The ACOG recommend that adults get 400 micrograms (mcg) of folic acid per day, which should increase to 600 mcg during pregnancy and then reduce slightly to 500 mcg when breastfeeding.

Non-invasive techniques

In the first trimester of pregnancy, screening by a combination of ultrasound markers (the nuchal translucency -NT) and maternal serum α -hCG (human chorionic gonadotropin) and PAPP-A (pregnancy associated plasma protein - A) can identify up to 97% of fetuses with trisomy 21 and other major chromosomal abnormalities. Collection of blood for biochemical analysis is performed between 9 and 13 6/7 weeks'

gestation .

Second-trimester maternal serum testing includes the triple and quadruple screens. Multiple marker screening is used in the second trimester (15–20 weeks) to screen for trisomies 21 and 18 as well as open neural tube defects. The quadruple screen is the measurement of alpha fetoprotein (AFP), human chorionic gonadotropin (hCG), unconjugated estriol (uE3), inhibin A levels in maternal serum. This combination of markers can detect approximately 60% of cases of fetal Down syndrome with a false positive rate of approximately 4% .

Second trimester ultrasonography may identify fetal anatomic defects, such as congenital heart defect or markers suggestive of fetal aneuploidy like a thickened nuchal fold, absent nasal bone, renal pyelectasis, or echogenic bowel.

The advantages of this non invasive method are the aiming to reduce the number of women undergoing invasive prenatal diagnosis, as well as increase the proportion of Down's syndrome detection.

Invasive techniques

Prenatal diagnosis of chromosomal abnormalities is currently accomplished by invasive techniques, such as amniocentesis and chorionic villus sampling (CVS).

CVS is performed in the first trimester from 10 through 13 weeks' gestation, whereas amniocentesis can be performed starting at 15 weeks' gestation.

Fetal chromosome analysis has been traditionally performed using Giemsa banding (G-banding) of cultured cells in metaphase and is considered the gold standard detection method. This technique is accurate and reliable allowing the detection of a variety of numerical and structural aberrations. The diagnostic accuracy of karyotyping with amniocentesis is 99.4–99.8% and for CVS 97.5–99.6% . The primary disadvantage of the conventional cytogenetics is that the prenatal tissue must be cultured for several days prior to analysis. It takes 10 days to obtain results and has a culture failure rate of about 1% .

Advances in molecular genetics, using either fluorescence in situ hybridization (FISH) or quantitative fluorescence-polymerase chain reaction (QF-PCR) , can be applied to give karyotype results within one or two days. Fluorescence in situ hybridization on uncultured amniotic fluid cells using chromosome-specific DNA probes offers the opportunity for rapid

screening of aneuploidies and has become an integral part of the current practice in many clinical cytogenetics laboratories. Aneuploidies involving chromosomes 13, 18, 21, X and Y account for the majority of all chromosome abnormalities in live-born infants. Rapid diagnosis of fetal chromosome anomalies may facilitate clinical decision making, especially when a fetal abnormality is detected late in pregnancy.

CONCLUSION

Case of interest because the mother has not taken pre and post conceptional folic acid

Mother was counselled regarding the importance of NT scan & other scan.

As earlier diagnosis would be helpful in earlier intervention if needed.

Mother is under continuous follow up.

REFERENCES

1. Divane A, Carter N P, Ferguson-Smith MA. Rapid prenatal diagnosis of aneuploidy from uncultured amniotic fluid cells using five-color fluorescence in situ hybridization. *Prenat. Diagn.* 1994;14:1061–1069. [PubMed] [Google Scholar]
2. Whiteman DAH, Klinger K. Efficiency of rapid in situ hybridization methods for prenatal diagnosis of chromosome abnormalities causing birth defects. *Am. J. Hum. Genet.* 1991;49:A1279–A1279. [Google Scholar]
3. Koken G, Derbent A, Erol O, et al. Awareness and use of folic acid among reproductive age and pregnant women Department of Obstetrics and Gynaecology. Antalya Education and Research Hospital, Antalya, Turkey; 2013.
4. Rofail D, Colligs A, Abetz L, Lindemann M and Maguire L. Factors contributing to the success of folic acid public health campaigns. *J Public Health (Oxf)*. 2011; 34(1): 90–99. DOI: 10.1093/pubmed/fdr048-DOI-PMC-PubMed

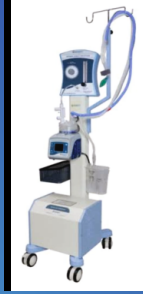

DR.K.VIJAYA PRABHA CHEZHIAN , MBBS,DGO,FICOG
SHAKTHI HOSPITAL, LALGUDI

POEM

இயற்கை அன்னை அரவணைப்பில் இறைவனை நித்தம் உணர்வோமே

வெள்ளத்தனையது மலர்நீட்டம் மாந்தர்தம்
உள்ளத்தனையது உயர்வு
வண்ணாங்களால் காண்பவர் மனத்தை
கொள்ளைக் கொள்ளும்
சிறகடித்து வாழ்க்கையை சந்தோஷமாய்
எதிர்நோக்கும்
வண்ணத்துப் பூச்சிபோல் வாழ்வோமே
எண்ணங்கள் நல்லவை ஊற்றெடுக்குமே
தன் தலையில் அனைவருக்கும் இனிய பொக்கிஷம்
தாங்கிடும்
தென்னையைப் போல் சுயநலமின்றி
வாழ்வோமே
ஆலம் விழுதுபோல
அன்னை தந்தை பாதம் என்றும் வணங்கியே
தன்னைத் தானே உயர்த்தும் வாழியைத் தேடியே
எண்ண அலைகளை சீர்படுத்தி
மண்ணில் நல்ல வண்ணம் வாழ்வோமே.
இயற்கை அன்னை அரவணைப்பில்
இறைவனை நித்தம் உணர்வோமே



1/3, Ground floor, Viswappa Naicken pettai street,
(Opp) Fathima school, MAM Tower,
Puthur, Trichy - 620017.
Ph : 9047711999 Cell : 9413179276



Luprodex
Leuprolide Acetate for Injection (Depot 3.75mg/11.25mg)

LONOPIN Pen[®]

Low Molecule Weight Heparin Enoxaparin Sodium 300mg/3ml

LONOPIN 20 MG
40 MG
60 MG
Prefilled Syringe



Divo HMG HP / FSH
Highly Purified Human Menopausal Gonadotropin 75 IU / 150 IU

மகளிர் மருத்துவம்

- ❖ மகளிர் மற்றும் மகப்பேறு தீவிர சிகிச்சைப்பிரிவு
(HIGH RISK PREGNANCY)
- ❖ சினைப்பை நீர்கபடிகளுக்கான (PCOD)
சிறப்பு சிகிச்சை மையம்
- ❖ கர்ப்பை அகற்றுவதற்கான அதி நவீன லேப்ராஸ்கோப்பி
அறுவை சிகிச்சை மையம்
- ❖ குழந்தையின்மைக்கான சிறப்பு சிகிச்சை மையம்
- ❖ மார்பக / கர்ப்பை புற்றுநோய் கண்டறிதல்

வண்களுக்கான பிரத்தியேக
முழு உடல் யரிசோதனை வசதி உள்ளது.



கீதாஞ்சலி மெடிக்கல் சென்டர்

பிஷெவ்ரீபர் காலேஜ் மைதானம் எதிரில், வயலூர் ரோடு, புத்தூர், திருச்சி - 620 017
வசல் : 99429 66111 / 97158 99444 போன் : 0431 - 2776600





Social Security Scheme
of
The Federation of Obstetric & Gynaecological Societies of India
C-5,6,7,9,12,13, 1st Floor, D-Wing Entrance, Trade World, Kamala
City, Senapati Bapat Marg, Lower Parel West, Mumbai 400013.
Maharashtra, India
Tel : +91-022-24951648, 24951654, 24948032, 24948048
Email : membership@fogs.org Website : www.fogs.org



Dr.Hrshikesh D.Pai
Chairman
Mobile : 9820057722
Email : hdpai@hotmail.com

Dr.Madhuri Patel
Secretary General
Mobile : 9869042132
Email : drmadhuripatel@gmail.com

Dr. Asha Baxi
Vice Chairman
Mobile : 9826056576
Email : aabaxi@gmail.com

To,
All Members of
FOGSI

Dr.Geetendra Sharma
Vice Chairman
Mobile : 9825298762
Email :
geetendrasharma@yahoo.co.in

Sub : FOGSI – Social Security Scheme.

Dr. Sampathkumari S
Vice Chairman
Mobile : 9884813300
Email : drskumari@yahoo.co.in

Dear Members,

We are glad to inform you that FOGSI has launched a Social Security Scheme (SSS) for its members.

Dr. Yashodhara Pradeep
Vice Chairman
Mobile : 9838226666
Email : yashodhara27@gmail.com

The important feature of this scheme is that each member contributes Rs.300/- for every unfortunate death of the fellow member. On submission of Death Certificate by the nominee to the FOGSI Office, the office will dispatch the cheque to the nominee within 15 days without asking the cause of death. This money will be of great use to the nominee to complete the formalities / rituals after the unfortunate's demise of their beloved.

Dr. Alka Pandey
Vice Chairman
Mobile : 9525051132
Email : alkapandey06@yahoo.co.in

The fraternity amount will be directly proportional to the strength of SSS Membership. More the members, larger the amount will be available to the nominee.

Suvarna Khadilkar
Deputy Secretary General
Mobile : 9820078703
Email :
suvarnakhadilkar2@gmail.com

Thus we request all the FOGSI members to join the scheme, so that a handsome amount is gifted to the nominee upon their sad demise. If you are already a member than motivate others to join the scheme.

Dr.Parikshit Tank
Treasurer
Mobile : 9833255870
Email : pariktank@gmail.com

With regards,

Dr.Niranjan Chavan
Joint Treasurer
Mobile :9820123513
Email : nnchavan22@gmail.com

Thanking you,

Dr. Manisha Takhtani Kundnani
Joint Secretary
Mobile : 9833830031
Email : manishatakhtani@gmail.com

Yours sincerely,

M.A. Patel
Dr.Madhuri Patel
Secretary General
FOGSI-SSS

Dr.Alpesh Gandhi
Immediate Past Chairman
Mobile : 9825063582
Email : gandhialpesh@gmail.com

Encl : Application form + Details.

Dr.Jaydeep Tank
Chairman Elect
Mobile : 9820106354
Email : drjaydeeptank@gmail.com

Dr.Ameya Purandare
Co-opted member
Mobile : 7738022440
Email:drameyap@gmail.com

FOGSI – Social Security Scheme : Salient Features

Membership Criteria

1. Life / Ordinary member of a constituent society of FOGSI for not less than three consecutive years at the time of joining this scheme.
2. Membership of this scheme shall be subject to continuously being an active member of FOGSI, throughout the duration of membership of the FOGSI Social Security Scheme.
3. This must be accompanied by an endorsement by the President / Secretary of the member society to which the applicant belongs.

Age Criteria

1. The age will be considered as age in completed years on the date of encashment of the draft / cheque received.
2. Proof of age must be attached with application.

<u>Age</u>	<u>Admission Fee Rate</u>
At or below 30 years	Rs.1,000/-
Between 31 and 40 years	Rs.2,000/-
Between 41 and 50 years	Rs.3,000/-
Between 51 and 60 years	Rs.5,000/-
Above 60 years	Rs.10,000/-

Membership Fee

Every member of this scheme shall pay Rs.100/- as membership fees. The membership fee is non-refundable.

Advance Fraternity Contribution

Every member has to pay initially Rs.1,500/- as A.F.C. along with the admission fee and membership fee, which will be adjusted as Rs.300/- (Death Fraternity Contribution) per death of member during the year.

Fraternity Benefit

1. Benefit of fraternity contribution of the scheme is available to nominees of scheme members after completion of two years of membership of FOGSI S.S.S. An exception is made to this clause in the first two years of this scheme.
2. If the death of a member occurs in an accident after joining the scheme, the nominee has to present the police file number and post mortem report.
3. On receipt of information from a nominee about the death of the member, his/her nominee shall be paid the fraternity contribution as per entitlement under this scheme and the balance if any lying in A.F.C. account of member.

Death Fraternity Contribution (D.F.C.)

1. Every member of the scheme shall contribute D.F.C. of Rs.300/- in the event of death of a member.
2. This amount shall be adjusted against the A.F.C. during the year.
3. Out of the above amount, Rs. 270/- shall be paid to the nominee of deceased member, with Rs. 30/- being retained by this scheme, for utilization for administrative expenses and to bridge any problem shortfall in overall D.F.C. collection.

Mode of Payment

The payment is to be made by cheque / draft payable in Mumbai, drawn in favour of **“FOGSI-S.S.S.”**.

OR

Through QR Code



Details about the Payment

Age	Admission Fee	Membership Fee	Advance Fraternity Contribution	Total Amount
At or below 30 years	Rs. 1,000/-	Rs. 100/-	Rs. 1,500/-	Rs. 2,600/-
31 and 40 years	Rs. 2,000/-	Rs. 100/-	Rs. 1,500/-	Rs. 3,600/-
41 and 50 years	Rs. 3,000/-	Rs. 100/-	Rs. 1,500/-	Rs. 4,600/-
51 and 60 years	Rs. 5,000/-	Rs. 100/-	Rs. 1,500/-	Rs. 6,600/-
Above 60 years	Rs. 10,000/-	Rs. 100/-	Rs. 1,500/-	Rs. 11,600/-

Every member of the scheme shall contribute D.F.C. of Rs.300/- in the event of death of a member.

** If a member furnishes any wrongful information in the application form or at any time during the membership term, the Managing Committee of this scheme shall have the right to terminate the membership of the member concerned without any benefit.*



The Federation of Obstetric & Gynaecological Societies of India

C-5,6,7,12,13, 1st Floor, D-Wing Entrance, Trade World, Kamala City,
Senapati Bapat Marg, Lower Parel West, Mumbai 400013. Maharashtra, India

* Tel : +91-022-24951648, 24951654, 24948032, 24948048
*Email : membership@fogsi.org *Website : www.fogsi.org

**Membership Form
FOGSI – Social Security Scheme**

Personal Details :-

Name : _____

Age : _____ Date of Birth : _____ Sex : _____

Address: _____

City : _____ Pincode : _____ State : _____

Contact Numbers : _____ Email : _____

Name of the Parent Society : _____

Life Member : Yes / No Duration of Membership : _____ years

Nomination Details :-

Name of the Nominee : _____ Relationship : _____
(Full name)

Alternate Nominee : _____ Relationship : _____
(Full name)

Membership Contribution :-

Admission Fees(As recommended): Rs. _____ (Please attached age proof).

Membership Fee : Rs.100/-

Advance Fraternity Contribution : Rs.1,500/-

Total Amount Paid : Rs. _____ by Cheque / Demand Draft No. _____

dated _____ Bank : _____

Signature of Applicant

To be filled by the Member Society (Certificate by the Member Society)

This is to Certify that Dr. _____ is a continuous active
Member of the Society for the last _____ years.



Signature of the President / Secretary

For Office Use Only

FOGSI Membership No. : _____ Application No. _____

Receipt No. _____ dated _____

Office Superintendent

Treasurer

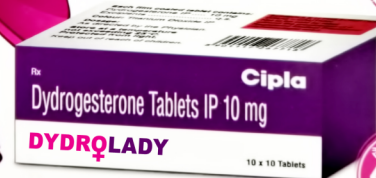In Infertility due to Luteal insufficiency,
Threatened & Habitual Miscarriage

®
DYDROLADY
Dydrogesterone Tablets IP 10 mg

Caring for precious Pregnancy

Hypromellose Infused Technology#

- Controlled Release over prolonged duration¹
- Classified as GRAS by FDA¹



Ensure she is in the
Pink of Health!

In Iron Deficiency Anaemia

New
cpink®

Ferrous Ascorbate SR 100 mg + L-Methylfolate 0.5 mg

Cipla

*Thank you for your
immense support*

- Journal Team

